



eISSN 2279-7483

<https://www.pagepressjournals.org/index.php/vl/index>

**Publisher's disclaimer.** E-publishing ahead of print is increasingly important for the rapid dissemination of science. The **Early Access** service lets users access peer-reviewed articles well before print / regular issue publication, significantly reducing the time it takes for critical findings to reach the research community. These articles are searchable and citable by their DOI (Digital Object Identifier).

**Veins and Lymphatics** is, therefore, e-publishing PDF files of an early version of manuscripts that have undergone a regular peer review and have been accepted for publication, but have not been through the typesetting, pagination and proofreading processes, which may lead to differences between this version and the final one. The final version of the manuscript will then appear in a regular issue of the journal.

E-publishing of this PDF file has been approved by the authors.

*All legal disclaimers applicable to the journal apply to this production process as well.*

Veins and Lymphatics 2024 [online ahead of print]

To cite this article:

Eugenio Martelli, Laura Capoccia, Giovanni Sotgiu, et al. Crossotomy vs crossectomy for saphenous vein sparing surgery in patients with varicose veins due to ostial incontinence: protocol for double blind, multicenter, randomized trial. *Veins and Lymphatics*. 2024;13:12146. doi:10.4081/vl.2024.12146

 ©The Author(s), 2024  
Licensee PAGEPress, Italy

**Crossotomy vs crossectomy for saphenous vein sparing surgery in patients with varicose veins due to ostial incontinence: protocol for double blind, multicenter, randomized trial**

Eugenio Martelli<sup>†,1,2,3</sup>, Laura Capoccia<sup>†4</sup>, Giovanni Sotgiu<sup>5</sup>, Laura Saderi<sup>5</sup>, Mariangela Valentina Puci<sup>5</sup>, Piero Modugno<sup>6</sup>, Sergio Furgiuele<sup>7</sup>, Vincenzo Aversano<sup>8</sup>, Salvatore De Vivo<sup>9</sup>, Luca Iorio<sup>10</sup>, Allegra Rosa Martelli<sup>11</sup>, Stefano Ricci<sup>12</sup>

<sup>1</sup>Department of General and Specialist Surgery, Faculty of Pharmacy and Medicine, Sapienza University of Rome;

<sup>2</sup>Saint Camillus International University of Health Sciences, Rome;

<sup>3</sup>Division of Vascular & Endovascular Surgery, Department of Surgery, S. Maria Goretti Hospital, Latina;

<sup>4</sup>Division of Vascular & Endovascular Surgery, Department of Cardiovascular Sciences, S. Anna and S. Sebastiano Hospital, Caserta;

<sup>5</sup>Clinical Epidemiology and Medical Statistics Unit, Department of Medicine, Surgery and Pharmacy, University of Sassari;

<sup>6</sup>Division of Vascular Surgery, I.D.I. Hospital, Rome;

<sup>7</sup>Division of Vascular Surgery, Struttura Ospedaliera Mediterranea, Naples;

<sup>8</sup>Division of Angiology, Villa Fiorita Clinic, Capua (CE);

<sup>9</sup>Division of Vascular Surgery, Pellegrini Hospital, Naples;

<sup>10</sup>Division of Vascular Surgery, Campobasso Hospital;

<sup>11</sup>Medicine and Surgery School of Medicine, Campus Bio-Medico University of Rome;

<sup>12</sup>Private practice in Phlebology, Rome, Italy;

†EM and LC have contributed equally

**Corresponding author:** Eugenio Martelli, S. Maria Goretti Hospital, Via Lucia Scaravelli, 04100 Latina, Italy.

Tel. (+39)3294003220. E-mail: [eugenio.martelli@uniroma1.it](mailto:eugenio.martelli@uniroma1.it)

**Key words:** varicose veins; great saphenous vein; femoral vein; high ligation; neovascularisation recurrences.

**Authors' contributions:** conception and design, SR; analysis and interpretation of data, EM, LC, GS, LS, MVP, PM, SF, VA, SDV, LI, ARM; drafting the article, EM, LC, SR; revising the article critically for important intellectual content, GS, LS, MVP, PM, SF, VA, SDV, LI, ARM. All the authors have read and approved the final version of the manuscript and agreed to be held accountable for all aspects of the work. †EM and LC have contributed equally.

**Conflict of interest:** the authors declare no conflict of interest.

**Funding:** none.

**Availability of data and materials:** all data generated or analyzed during this study are included in this published article.

Accepted for presentation at the annual meeting of the American Venous Forum, Tampa (FL, USA), March 3-6, 2024.

## Abstract

Double-blind/multicenter/randomized trial protocol.

Eligibility criteria: age 18-70 yrs; C2-C5 leg varices secondary to the Great Saphenous Vein (GSV) incontinence; GSV size 6-10mm, at 10cm from the Saphenous-Femoral Junction (SFJ); ostial reflux lasting >0.5 sec at duplex ultrasound; negative reflux elimination test; acceptance of the GSV sparing treatment plus partial/total varicose veins removal.

Exclusion criteria: non-isolated GSV reflux; district already treated; pregnancy/lactation; impaired walking ability; deep vein thrombosis/insufficiency; severe comorbidities.

Participants recruited from 7 Italian tertiary referral centres. Interventions: crossotomy (no SFJ's tributaries ligation) vs crossotomy.

The study aimed to verify if GSV drainage through the SFJ's tributaries reduces groin/peripheral recurrences.

Primary endpoint: 1-year GSV reflux recurrence, positive to the Valsalva maneuver, originating from the SF.

Participants equally randomized. Participants, care givers, and those assessing the outcomes blinded to group assignment.

## Introduction

### *Scientific background and explanation of rationale*

One possible cause of inguinal recurrence after traditional surgery for Great Saphenous Vein (GSV) incompetence is the abolition of the physiological drainage of the Saphenous-Femoral Junction (SFJ) Descending Tributaries (DT), when interrupted.<sup>1</sup> GSV stripping, preceded by its section and flush ligation with the femoral vein, impairs the drainage of the superficial tissues of the lower limb, while the ligation of the DT of the SFJ impairs the drainage of the superficial tissues of the lower abdominal wall.

Allowing drainage to the DT during GSV ablation could reduce the number of recurrences. This has been suggested by several studies, where a GSV long stump was left allowing the physiologic DT drainage through the SFJ.<sup>2-3</sup>

A different approach is saving the SFJ DT maintaining their drainage in the preserved GSV trunk, as suggested by the CHIVA (Conservatrice Hémodynamique de l'Insuffisance Veineuse en Ambulatoire) treatment, in the hypothesis to limit recurrences.<sup>4,5</sup>

### *Hypotheses*

In a perspective of GSV conservative surgery, this study protocol aims to investigate if the flush SFJ interruption maintaining the DT drainage in the saphenous stem (crossotomy) is advantageous compared to the traditional flush SFJ interruption with DT ligation (crossectomy), to avoid groin neo-vascularization formation and limit anarchic recurrences by leaving the draining GSV.<sup>6</sup> Both surgical arms are regularly accepted as correct procedures in the current literature.

## Materials and Methods

This study protocol follows the checklist reported in the CONSORT guidelines.<sup>7</sup>

### *Trial design*

This is a multicenter, equally randomized (1:1 for two groups allocation ratio), double-blind, trial protocol involving seven Italian divisions of Vascular Surgery. Each Centre must first obtain permission from its Ethical Committee to join the study. No changes to methods are expected after trial commencement.

### *Participants*

#### *Eligibility criteria*

- age between 18 and 70 yrs;
- clinical class C2-C5 leg varices, according to Clinical Etiologic Anatomic Pathophysiologic classification, suitable for phlebectomies, secondary to the GSV incontinence;
- GSV size between 6 and 10 mm, at 10 cm from the SFJ;
- reflux of ostial origin lasting more than 0.5 sec at Duplex Ultrasound (DUS); the terminal valve of the common femoral vein is considered incompetent on DUS when Valsalva and/or calf squeeze maneuvers produce GSV reflux;<sup>8</sup>
- acceptance of the GSV sparing treatment -plus partial/total varicose veins removal- by signing a written informed consent;
- negative Reflux Elimination Test (RET);<sup>9</sup>

RET is negative when GSV reflux doesn't disappear after digital compression of the varicose vein, eventually at the passage point of the reflux from the GSV to the supra-fascial tributary. This is due to the presence of at least one distal re-entry perforator on the GSV (Figure 1).

RET is positive when the reflux disappears after digital compression of the varicose vein (Figure 2).

In case of RET positivity, the reflux is drained by a re-entry positioned on the varix. The GSV axis does not have its own drainage of blood refluxing. So, after phlebectomy of the varix the GSV can be emptied only towards the SFJ: in fact, the GSV no longer has reflux. In this case, the eventual interruption of the SFJ without saphenectomy would favour GSV thrombosis. Therefore, this case does not allow GSV saving except if through a two-stage tactic (CHIVA II crossotomy), after waiting for the creation of a new distal perforator on the GSV axis.<sup>6</sup>

These cases aren't included in our study.

We consider only negative RET cases, *i.e.* those in which the GSV drains the reflux through a distal perforator placed on its axis: so, even after interrupting the SFJ, a retrograde flow remains in the saphenous axis. The inclusion of the RET negative patients only, generally representing 30% of all the GSV refluxing cases, makes reaching the required numbers more complex.

#### *Exclusion criteria*

- pelvic reflux, or not-isolated GSV reflux;
- district already treated;
- pregnancy and lactation;



- a defective calf muscular pump, or impaired walking ability;
- (history of) deep vein thrombosis/insufficiency;
- diabetes; severe renal, hepatic, cardiorespiratory, autoimmune diseases; malignancy;

Participants will be recruited from 7 tertiary referral centres in 3 contiguous Italian regions, namely: Lazio (the Divisions of Vascular Surgery of S. Maria Goretti Hospital in Latina, and I.D.I. Hospital in Rome), Campania (the Divisions of Vascular Surgery of S. Anna and S. Sebastiano Hospital in Caserta, Pellegrini Hospital and Struttura Ospedaliera Mediterranea in Naples, and the Division of Angiology of Villa Fiorita Clinic in Capua, CE), and Molise (the Division of Vascular Surgery of Campobasso Hospital).

### ***Interventions***

Grading of the varicosity extension accomplished according to Pittaluga *et al.*<sup>10</sup> Each of the 4 faces of the limb (posterior, medial, anterior, lateral) divided into 8 parts (total = 32 zones) in the pre-operative map: 3 zones for the thigh, 3 zones for the calf, 1 for the knee, and 1 for the foot. Extension of varicosity classified in: A=1-2 zones (limited phlebectomy); B=3-7 zones (medium-extension phlebectomy); C>7 zones (extensive phlebectomy).

Body Mass Index (BMI), gender, age, and DUS examination in standing position (evaluation of GSV reflux, incontinence of ostial origin, positive Valsalva and compression/release maneuvers, calibre at 10 cm from the SFJ, RET, and supra-GSV femoral valve continence) will be recorded as well.

All patients must answer to the Chronic Venous Insufficiency Questionnaire (CIVIQ-20) and Venous Clinical Severity Score (VCSS) before surgery, and at follow-up.<sup>11,12</sup>

After varicosities mapping by DUS, local anaesthesia adopted for all the patients enrolled and stab phlebectomies of prevalent varicosities performed, with isolation of the GSV stem.

The SFJ interruption will be randomized at this time between the following two techniques, without stripping.

A) Crossotomy: flush SFJ ligation preserving the DT for the maintenance of the GSV flow, to keep it open and functioning (group A, Figure 3). Blood-flow is discharged through the distal GSV perforators, necessarily preserved and functioning.<sup>4-6</sup>

B) Crossectomy: flush SFJ ligation with accurate interruption of all the DT, but with the preservation of the GSV (group B, Figure 4). The rationale is that the ablation of the distal saphenous axis is not essential to varicose treatment, and unnecessarily aggressive.

SFJ will be ligated with a 3/0 non absorbable suture, with a clip placed longitudinally under the ligature to avoid any residual stump on the femoral vein. The clip will be positioned using a 90 degrees clip-positioner, to avoid angled positioning. It will pinch the femoral wall, and the free extremities of the clip will be strictly joined to each other, without any interposition of biological material. Then, the divided GSV stump will be sutured by non-absorbable 3/0 suture.<sup>6</sup> Operating times will be calculated.

Post-operative treatment standardized: immediate walking, 7 days strong analgesic hemostatic compression, 7-15 days additional local compression if necessary, and elastic stockings

hereinafter. Physicians involved in the postoperative and follow-up controls will be blinded to the treatment performed. Analysis of the satisfaction degree by visual-analogue Pain Rating Scale from 0 to 10. Patients' Hospitalization will be calculated.

### **Outcomes**

At 7 days, possible post-operative pain, number of analgesics assumed, minimal/complete wound dehiscence, serosity, irritation, hematoma, or infection will be reported.

At 3 months, possible keloid or recurrent varicose veins will be assessed.

At 1 year, CIVIQ-20, VCSS, clinical examination for recurrence of varicosity (A, B, C), DUS for possible GSV reflux (positive to the Valsalva maneuver and originating from the SFJ), calibre, and patency will be performed.

Total costs will be calculated, and all data collected in an *ad hoc* database.

Primary outcome measure: 1-year GSV reflux positive to the Valsalva maneuver and originating from the SFJ.

Secondary outcome measures: GSV patency and calibre; 1-year peripheral recurrence (varicosity A, B, C); preoperative and 1-year quality of life; surgical complications; surgical time; PRS analysis of postoperative pain.

No change to trial outcomes after the trial commenced.

### **Sample size**

Based on 5-year recurrence rate of 1.1% and 7.4% after flush SFJ ligation with or without sparing of the DT<sup>2</sup>, respectively (ref), a significance level (alpha) of 0.05 and a statistical power

of 0.80, a total sample size of 320 estimated to be recruited (n=160 per single group). Recruitment completed in one year.

### ***Randomization***

A computer-generated randomization list will be employed, utilizing random number generation. Participants Enrollment will be equally randomized (1:1 allocation ratio).

Generation of the random allocation sequence, enrollment and assignment of participants to interventions will be performed by different nurses or physicians not interacting each other in the various steps of these processes.

### ***Blinding***

Participants, care providers, and those assessing outcomes will be blinded after assignment to interventions (crossotomy or crossectomy). Specifically, participants will be given a generic dismissal letter simply reporting “SFJ ligation and phlebectomies” (without specifying if crossotomy or crossectomy), and those assessing outcomes will not be the operators (Figure 5).

### ***Statistical methods***

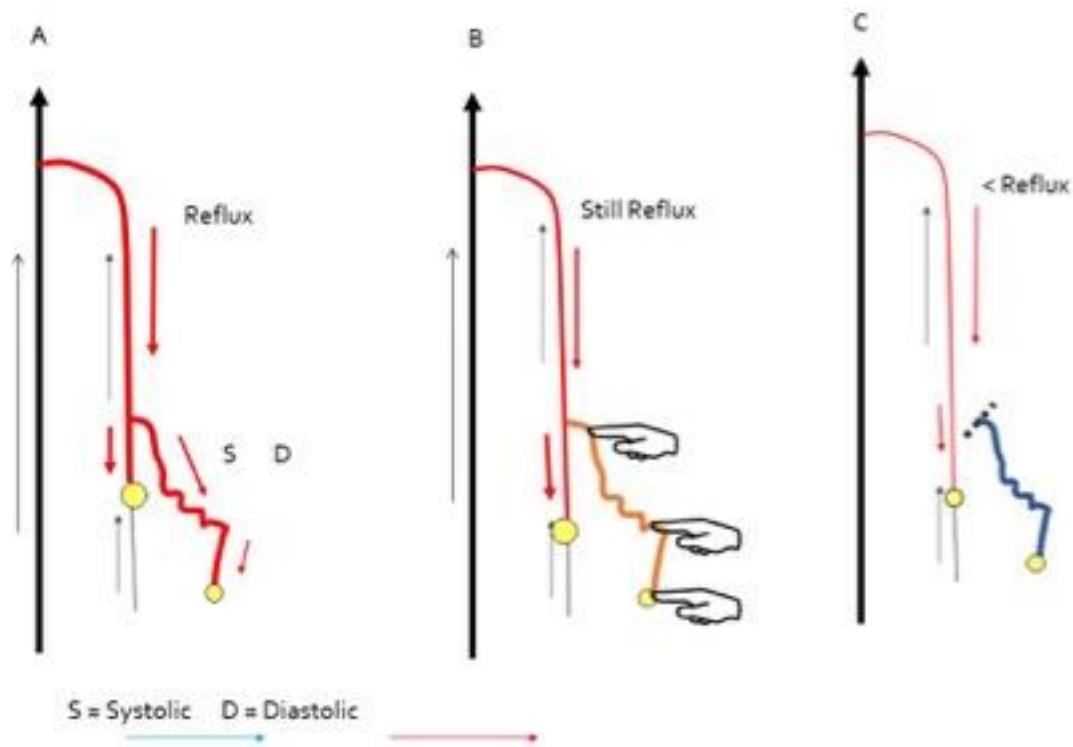
Demographic and baseline disease characteristics summarized with the use of descriptive statistics. Categorical variables reported as absolute numbers and percentages. Continuous variables reported as mean and Standard Deviation (SD), or median and Interquartile Range (IQR). Outcome differences between crossotomy and crossectomy will be evaluated using

Student t or Mann-Whitney tests for quantitative variables, in accordance with the Shapiro-Wilk normality test. Chi-squared or Fisher exact tests used for the comparison of qualitative characteristics. P-value <0.05 considered statistically significant. Statistical analyses will be conducted using STATA version 17.

## References

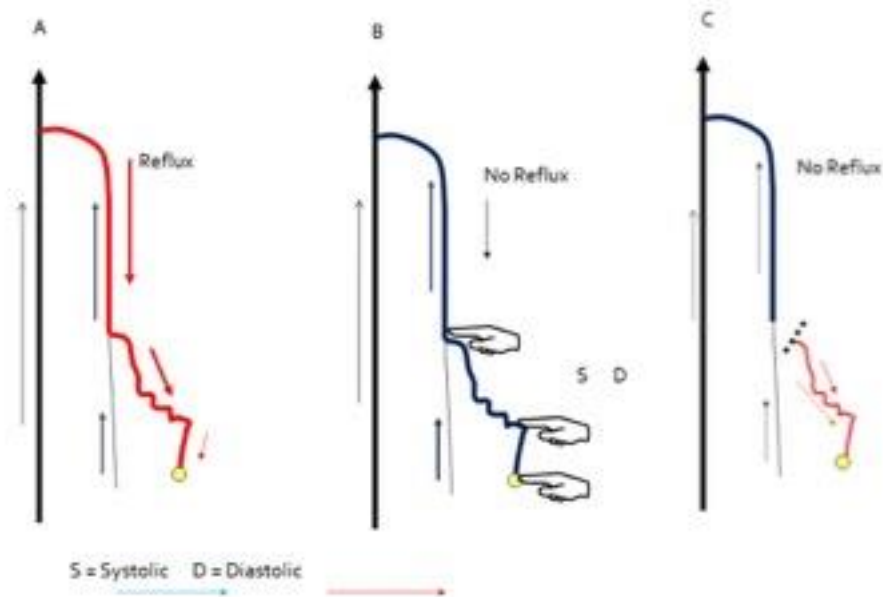
1. De Maeseneer M, Cavezzi A. Etiology and pathophysiology of varicose vein recurrence at the saphenofemoral or saphenopopliteal junction: an update. *Veins and Lymphatics*. 2012;1:e4.
2. Pagano M, Passaro G, Flore R, Tondi P. Inferior selective crosssectomy for great saphenous vein incompetence: Our experience. *Vascular*. 2021;29:290-6.
3. Casoni P, Lefebvre-Vilardebo M, Villa F, Corona P. Great saphenous vein surgery without high ligation of the saphenofemoral junction. *J Vasc Surg*. 2013;58:173-8.
4. Ricci S. The sapheno femoral junction involvement in the treatment of varicose veins disease. *Veins and Lymphatics*. 2017;6:6822.
5. Cappelli M, Molino-Lova R, Giangrandi I, et al. Ligation of the saphenofemoral junction tributaries as risk factor for groin recurrence. *J Vasc Surg Venous Lymphat Disord*. 2018;6:224-9.
6. Giancesini S, Delfrate R, Cappelli M, Mendoza E. CHIVA: surgical tips and tricks. In: Zamboni P, Mendoza E, Giancesini S, editors. *Saphenous Vein-Sparing Strategies in Chronic Venous Disease*. 1st ed. Cham (Switzerland): Springer; 2018 pp. 181-202.
7. Moher D, Hopewell S, Schulz KF, et al. CONSORT 2010 explanation and elaboration: updated guidelines for reporting parallel group randomised trials. *BMJ*. 2010;340:c869.
8. Zamboni P, Giancesini S, Menegatti E, et al. Great saphenous varicose vein surgery without saphenofemoral junction disconnection. *Br J Surg*. 2010;97:820-5.

9. Zamboni P, Cisno C, Marchetti F, et al. Reflux elimination without any ablation or disconnection of the saphenous vein. A haemodynamic model for venous surgery. *Eur J Vasc Endovasc Surg.* 2001;21:361-9.
10. Pittaluga P, Chastanet S, Rea B, Barbe R. Midterm results of the surgical treatment of varices by phlebectomy with conservation of a refluxing saphenous vein. *J Vasc Surg.* 2009;50:107-18.
11. Launois R, Mansilha A, Jantet G. International psychometric validation of the Chronic Venous Disease quality of life Questionnaire (CIVIQ-20). *Eur J Vasc Endovasc Surg.* 2010;40:783-9.
12. Vasquez MA, Munschauer CE. Venous Clinical Severity Score and quality-of-life assessment tools: application to vein practice. *Phlebology.* 2008;23:259-75.

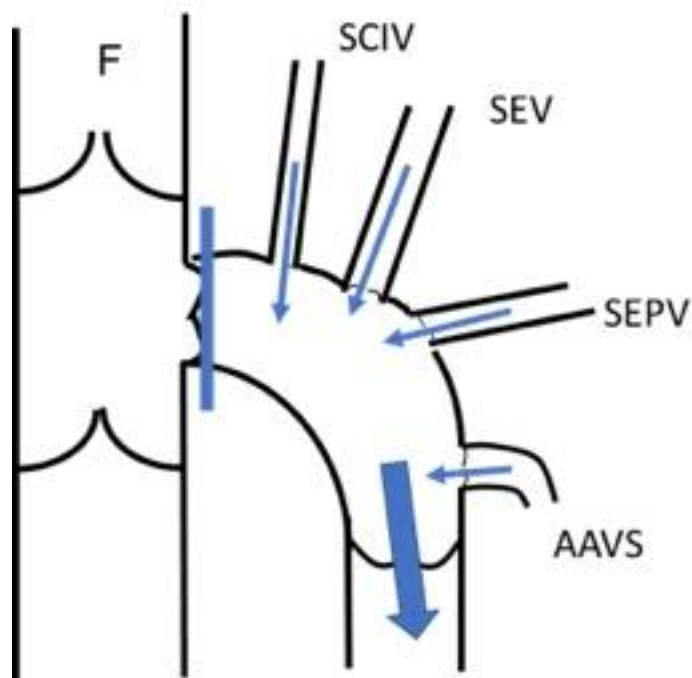


**Figure 1.** Negative RET: (A) when reflux re-entry is centred on the great saphenous vein (GSV) stem (even if not exclusively), (B) finger compression on the varix will not eliminate the reflux; (C) the same after a phlebectomy. In this case, interruption of the sapheno-femoral junction is indicated, since the GSV stem has a drainage based on a distal perforator.



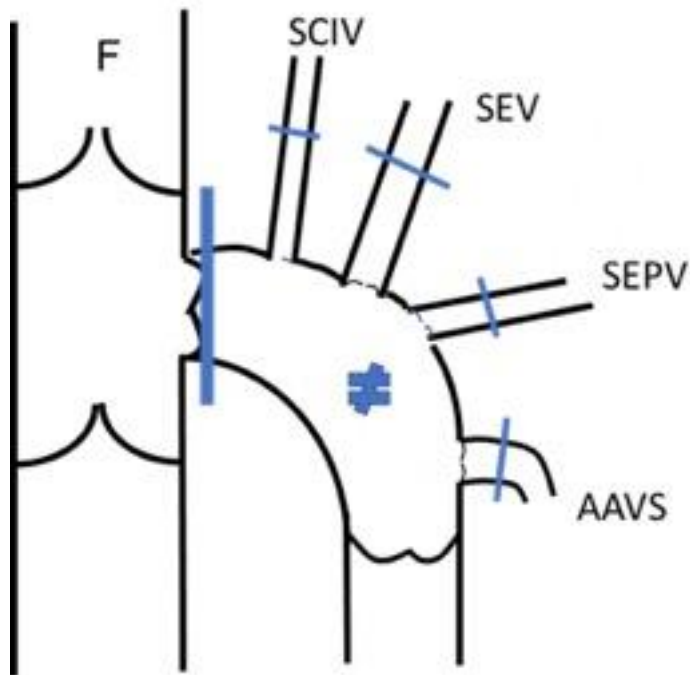


**Figure 2.** Positive RET: (A) the reflux re-entry is centred on a tributary varice; (B) the occluding digital compression on the varix makes the reflux disappear in the entire venous system; (C) tributary phlebectomy eliminate the reflux in the Great Saphenous Vein (GSV). In this case, the interruption of the sapheno-femoral junction is not necessary, and might cause thrombosis of the GSV.

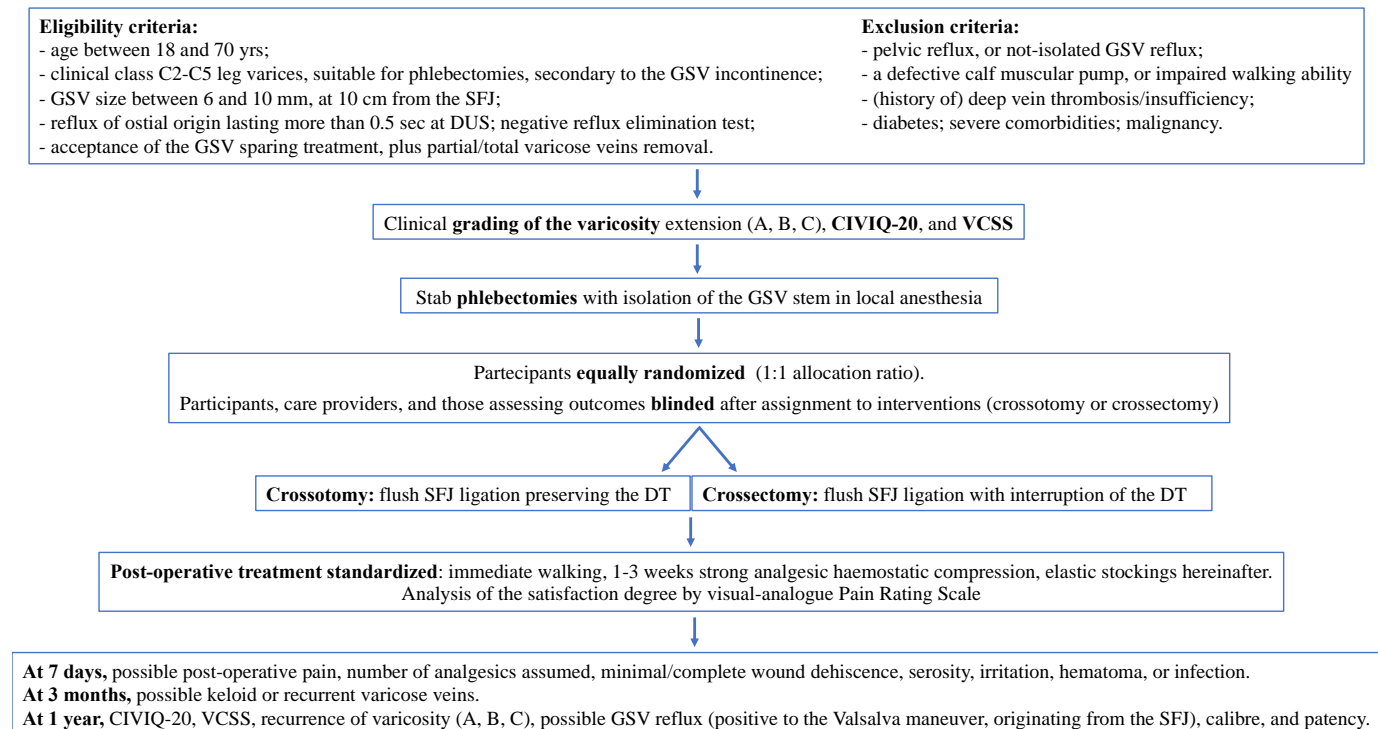


**Figure 3.** Crossotomy: only flush ligation of the sapheno-femoral junction.

F, Common Femoral Vein; SCIV, Superficial Circumflex Iliac Vein; SEV, Superficial Epigastric Vein; SEPV, Superficial External Pudendal Vein; AASV, Anterior Accessory Saphenous Vein.



**Figure 4.** Crossectomy: flush ligation of the sapheno-femoral junction and of all its tributaries. F, Common Femoral Vein; SCIV, Superficial Circumflex Iliac Vein; SEV, Superficial Epigastric Vein; SEPV, Superficial External Pudendal Vein; AASV, Anterior Accessory Saphenous Vein.



**Figure 5.** Flow diagram of the progress through the clinical phases of the trial.

GSV, Great Saphenous Vein; SFJ, Saphenous-Femoral Junction; DUS, Duplex Ultrasound; CIVIQ-20, Chronic Venous Insufficiency Questionnaire; VCSS, Venous Clinical Severity Score; DT, Descending Tributaries.