



SAVE THE SAPHENOUS: WHY ALL PATIENTS WITH SAPHENOUS REFLUX DON'T NEED AN ABLATION

MARGARET C. TRACCI, MD JD

UNIVERSITY OF VIRGINIA

8TH ANNUAL CURRENT CONCEPTS IN VASCULAR THERAPIES

HILTON VIRGINIA BEACH

VIRGINIA BEACH, VA APRIL 27, 2018

DISCLOSURES

- None

SAVE OUR SAPHENOUS?

**Vascular
Specialist**

SVS | Society for Vascular Surgery | Official Publication

COMMENTARY

Calling SOS -- Save Our Saphenous!


Publish date: November 21, 2013

By [Russell Samson, MD](#)



Dr. Russell H. Samson


THE WILD WEST



Removal of varicose veins with CHIV...
Estheticon.com
€2,000 ...

Visit Share

Related images:



View more

That was \$2432.22, as of yesterday, in case you were wondering
And yes, the floor nurses really appreciate the removal of all visible veins

RATIONALE

- Preserve the saphenous vein for future conduit
- Intervention on tributaries may improve saphenous function
 - Ascending/multifocal theory of venous insufficiency
- Equivalent symptomatic/cosmetic results?
- Acceptable rates of recurrence?

THEORIES OF DISEASE PROGRESSION

- The Descending/saphenocentric theory (“The Anthem theory”)
 - The first failure is within the proximal portion of the superficial system
 - Reflux first demonstrated at the valves of the SFJ and SPJ, deep venous pressure transmitted superficially
 - Progressive valvular incompetence propagates distally/peripherally
- The Ascending/multifocal theory
 - Venous reflux develops distally with creation of dilated venous reservoirs
 - Variceal tributaries transmit reflux to previously uninvolved segments
 - Reflux ascends cranially along the saphenous vein

PRINCIPAL TECHNIQUES

- Valvuloplasty: Primary or externally supported repair of the SFJ
- CHIVA: Ambulatory Conservative Hemodynamic Correction of Venous Insufficiency
- ASVAL: Ambulatory Selective Varices Ablation under Local Anesthesia

VALVULOPLASTY

- Theory: Descending reflux begins with failure of the junctional valves at the saphenofemoral junction, reflux and varicosities addressed by primary or externally supported repair
- Technique
 - Externally support valves at SFJ with cuff
 - Suture repair with or without visualization
- Drawbacks
 - Surgery
 - Neovascularization/recurrence

EXTERNAL CUFFS

INVITED COMMENTARY

Commentary re: Recurrence Rates Following External Valvular Stenting of the Saphenofemoral Junction: A Comparison with Simultaneous Contralateral Stripping of the Great Saphenous Vein

J.J. Bergan*

Vein Institute of La Jolla, 9850 Genese Avenue, Ste 410, La Jolla, CA 92037-1212, La Jolla, CA, USA

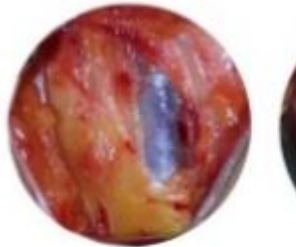
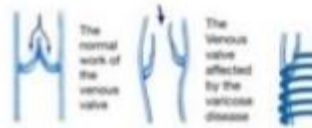
There was once a time in phlebologic history when the venocuff technique of varicose vein treatment with Saphenous vein preservation seemed important. At that time, the external wrap at the site of the terminal Saphenous valve was an ingenious approach that corrected venous insufficiency and maintained the integrity of the vein so that it could be used for coronary bypass.

Time has passed both of those ideas by and has also dealt with the varicose recurrences caused by neovascularization.

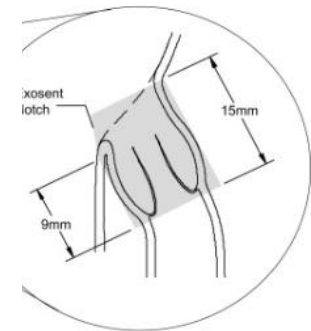
It is apparent that a groin incision leads to neovascularization and this, in turn is responsible for

some recurrent varicose veins. If there is no groin incision there is no neovascularization. Coronary bypass no longer requires a strong Saphenous vein; or any vein for that matter. And now, there are several ways to correct Saphenous reflux that do not require the technical surgery of days past. So this presentation is of historic interest and stands as a tribute to its inventor. But time passes many good ideas by and this is one that remains only of historic interest.

*Accepted 8 July 2007
Available online 22 August 2007*



The vein before the operation



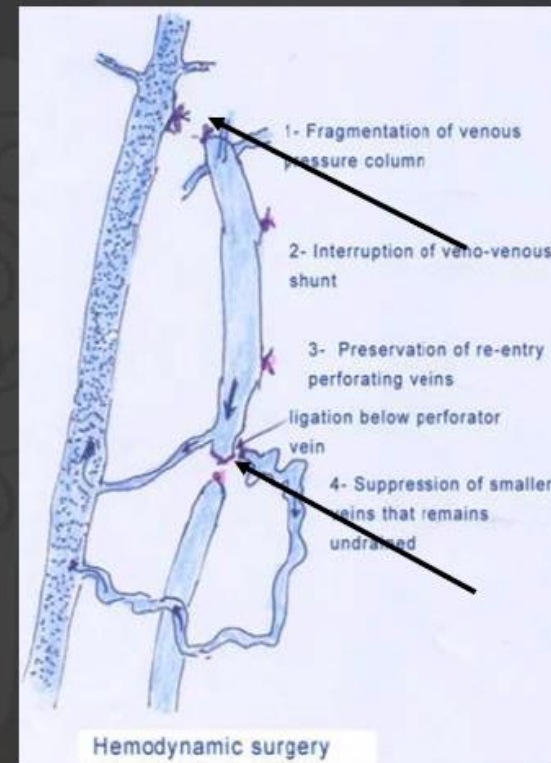
— Belt Attachment

— Phenotypic Marker

— Body

CHIVA Saphenous vein -> efficient way of drainage

- **Fragmentation of the column pressure & disconnection of the venous shunts with ligations**
- **Perform a system well-drained**
 - All isolated superf. segment drained in deep veins



CHIVA

- Theory: varicose veins result from pathological shunting from deep to superficial system. Selective interruption of nonfunctioning segments utilizes functioning segments of the superficial system and functioning perforating veins to effectively direct blood flow into a competent deep system.

Technique

- Map and mark
- Segmental ligation of saphenous vein to interrupt venous column of blood
- Interruption of incompetent connections between deep and superficial systems
- Preservation of competent perforating veins
- +/- Ligation of AAGSV, posterior medial tributaries

Drawbacks:

- Patient selection complex
 - Not suitable for obese patients
 - Contraindicated in the setting of significant deep venous reflux
- Technically complex: extensive mapping, marking, experience
- Limited reproducibility of results, poor results if incorrectly performed

CHIVA RESULTS

- Cochrane Review 2013
 - CHIVA versus compression
 - CHIVA versus vein stripping
 - CHIVA versus EVLA
- Onida and Davies Phlebology 2015
 - Widely variable recurrence (reflux in GSV) rates: range 18% at 10 years to 91% at 3 years
- Milone et al. G Chir 2011
 - “With experienced surgeons, CHIVA appears to be more effective than stripping in reducing the recurrence rate. However, when performed by an inexperienced surgeon the results are far worse than those achieved with stripping.”
 - “There was a clear reduction in recurrences at 5-10 years with CHIVA (stripping). However, if performed incorrectly, results are far worse with CHIVA. In fact, good results are far more difficult to achieve with CHIVA than stripping, which is repeatable and easy to perform.”

CHALLENGES...

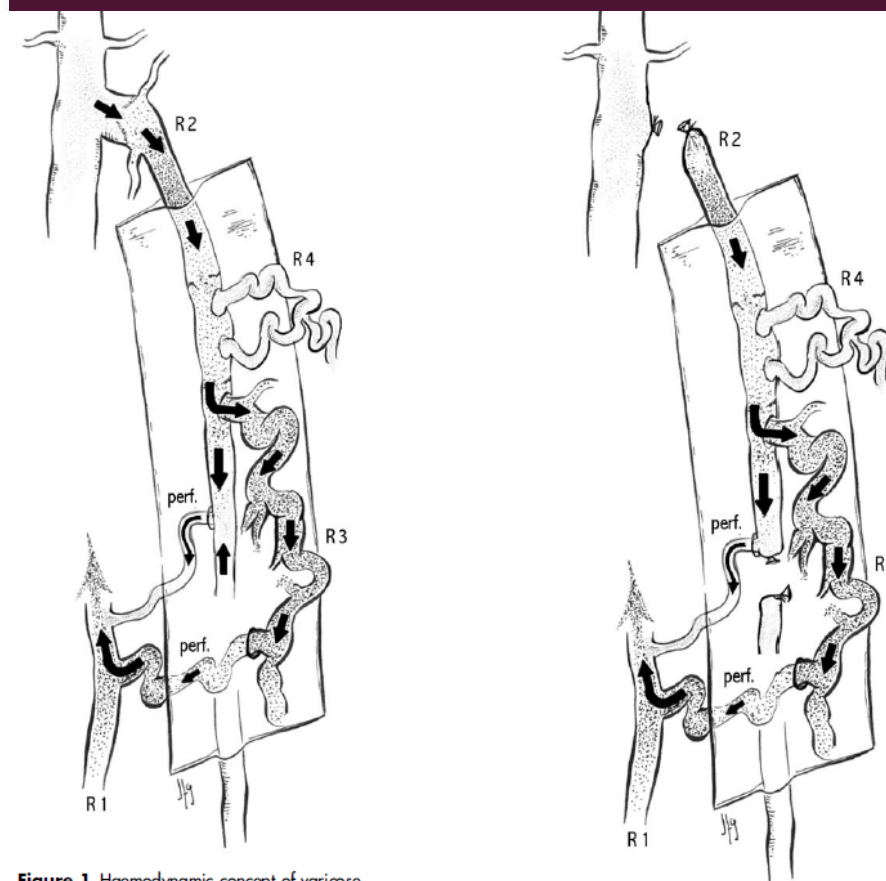
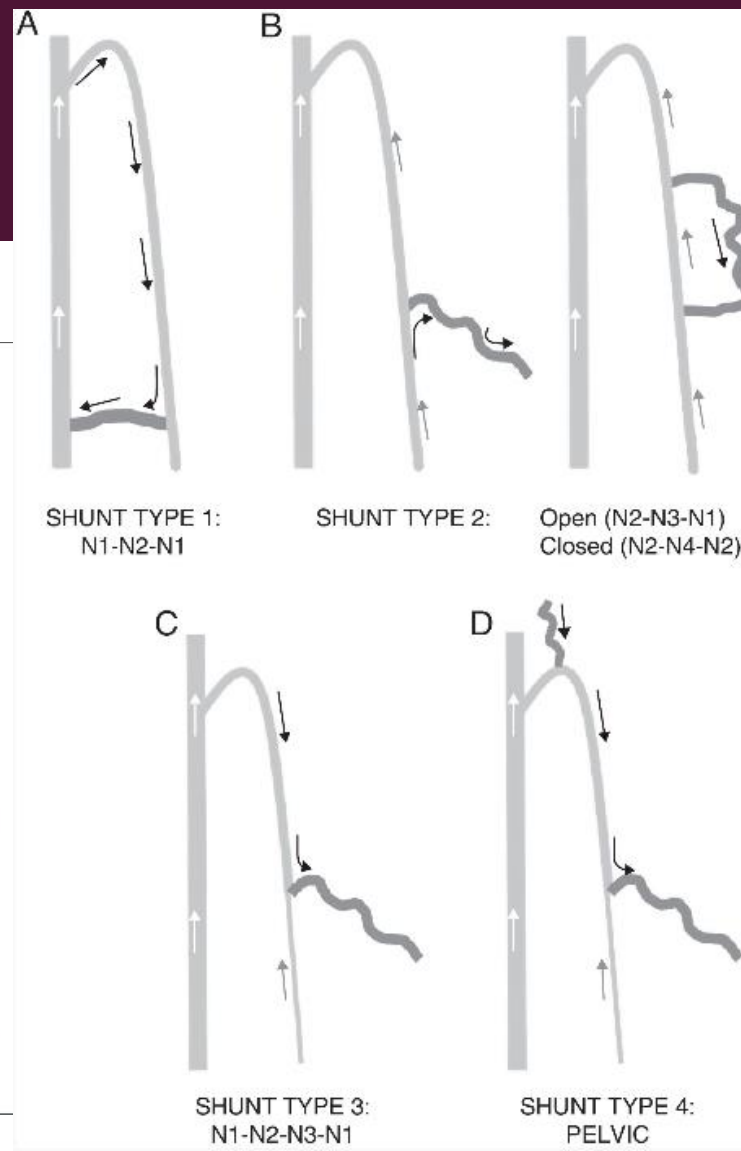
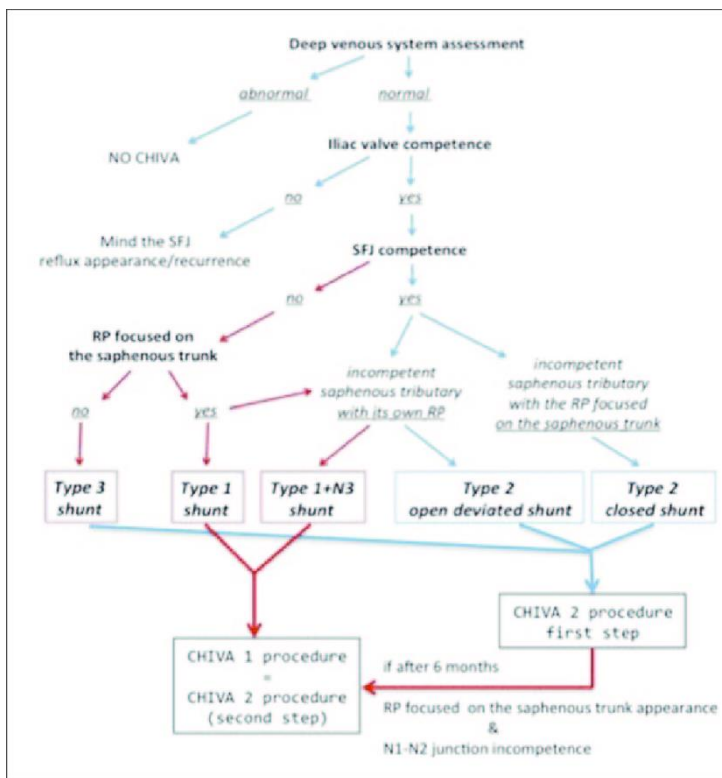


Figure 1 Haemodynamic concept of varicose veins: venous varices are the consequence of a pathological venous shunt that perpetuates recirculation of venous blood between the deep and superficial venous systems

Figure 2 Fragmentation of the venous pressure column is usually accomplished by ligation of the origin of the incompetent venous segments.



EXPERT SUMMARY

IL GIORNALE DI CHIRURGIA

[Home](#) > [Vol. XXXII](#) > [Vol. XXXII \(N. 11-12\) Abstract](#)

Recurrent varicose veins of the lower limbs after surgery. Role of surgical technique (stripping vs. CHIVA) and surgeon's experience

Milone M., Salvatore G., Maietta P., Sosa Fernandez LM., Milone F.
Original Article, 460 - 463

Abstract

Surgical treatment of varicose veins of the lower limbs resolves symptoms and improves quality of life. However, the high recurrence (20-80%) is a costly and complex issue. This is a retrospective review of 1489 patients with varicose vein of the lower limbs seen at our hospital between January 1980 and December 2005. The aim is to evaluate the effect of surgical technique (stripping vs. CHIVA) and surgeon's experience in reducing recurrences. With experienced surgeons, CHIVA appears to be more effective than stripping in reducing the recurrence rate ($p < 0.05$). However, when performed by an inexperienced surgeon the results are far worse than those achieved with stripping. There was a clear reduction in recurrences at 5-10 years with CHIVA than with conventional stripping. However, if performed incorrectly, results are far worse with CHIVA. In fact, good results are far more difficult to achieve with CHIVA than with stripping, which is repeatable and easy to perform.

ASVAL

- Theory: Based on the ascending theory of varicose vein development, targets dysfunctional tributaries.
- Technique:
 - Map and mark: Varicosities and saphenous vein are marked preoperatively in a standing position
 - Targeted varicosities removed using local anesthesia and preferred technique of phlebectomy
- Drawbacks:
 - Compromised by SFJ reflux, large (>1 cm) saphenous vein
 - May not be suitable in obese patients
 - Most data in C2-C4 patients

ASVAL RESULTS (IN EXPERT HANDS)

- Pittaluga et al. JVS 2009
 - Reflux eliminated (>0.5sec) in 66.3% of limbs at 4 years
 - 88.5% freedom from variceal recurrence
 - 78% patients symptom-free at 4 years

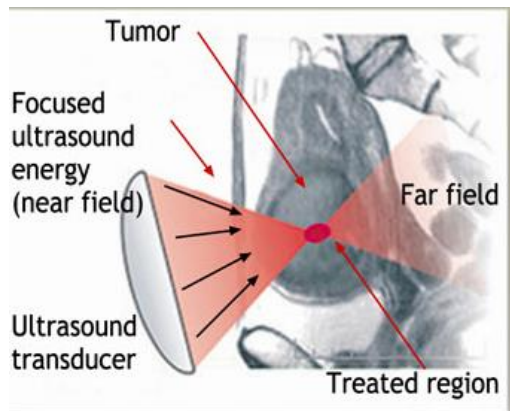
- Pittaluga and Chastanet Phlebology 2015
 - Persistent/recurrent saphenous reflux- 33.8% cumulative incidence at 5 years
 - Recurrent varicose veins- 13% cumulative incidence at 5 years
 - Major secondary procedure- 4.5% cumulative incidence at 5 years

MODIFIED ASVAL

- Technique: Targeting of incompetent saphenous tributaries by endovenous (EVLA) targeting of proximal straight segments, followed by ultrasound-guided foam sclerotherapy of the remainder of remainder of these varicosities

FUTURE DIRECTIONS

- Focused ultrasound?
- Endovenous valve replacement?



J Vasc Surg. 2010 Mar;51(3):707-11. doi: 10.1016/j.jvs.2009.10.049. Epub 2010 Jan 4.

A portable high-intensity focused ultrasound device for noninvasive venous ablation.

Henderson PW¹, Lewis GK, Shaikh N, Sohn A, Weinstein AL, Olbricht WL, Spector JA.



European Journal of Vascular and
Endovascular Surgery

Volume 46, Issue 3, September 2013, Pages 360-365



Endovenous Valve Transfer for Chronic Deep Venous Insufficiency

M.N. Phillips ^{a, b}, M.L. Dijkstra ^b, N.Y. Khin ^c, R.J. Lane ^{a, b, c, d, e} ✉

SUMMARY

- Not all varicose veins require saphenous ablation for effective treatment
- CHIVA and ASVAL techniques well described, may improve function of preserved saphenous vein
- CHIVA may completely or partially preserve saphenous
 - Focus on isolating poorly functioning segments, redirecting flow centrally
 - Very technically demanding of lab and operator, extensive mapping time consuming
 - Reproducibility challenging, incorrect approach may worsen symptoms
 - Not suitable with significant deep reflux
- ASVAL and modified ASVAL
 - Focus on varicose/incompetent tributaries of saphenous
 - May not be suitable with significant SFJ reflux
- Limited insurance coverage
- New technologies?

REFERENCES

- Onida S, Davies AH. CHIVA,ASVAL and related techniques- Concepts and evidence. Phlebology 2015;30(2S):42-45.
- Pittaluga P, Chastanet S, Rea B, Barbe R. Midterm results of the surgical treatment of varices by phlebectomy with conservation of a refluxing saphenous vein. J Vasc Surg 2009;50:107-18. (ASVAL)
- Pittaluga P, Chatanet S, Locret T, Barbe R. The effect of isolated phlebectomy on reflux and diameter of the great saphenous vein: A prospective study. Eur J Vasc Endovasc Surg 2010;40:122-128. (ASVAL)
- Carandina S, Mari C, De Palma M, Marcellino MG, Cisno C, Legnaro A et al. Varicose vein stripping vs. haemodynamic correction (CHIVA): A long term randomised trial. Eur J Vasc Endovasc Surg 2008;35: 230-7. (CHIVA)
- Pares JO, Juan J, Tellez R, Mata A, Moreno C, Quesr FX et al. Varicose vein surgery: stripping versus the CHIVA method: a randomized controlled trial. Ann Surg 2010;251:624-31 (CHIVA)
- Zmudinski M, Malo P, Hall C, Hayashi A. CHIVA- A prospective study of a vein sparing technique for the management of varicose vein disease. Am J Surg 2017;213:967-969 (CHIVA)
- Gloviczki P et al. The care of patients with varicose veins and associated chronic venous diseases J Vasc Surg 2012;53(16S): 2S-43S