

Treatment of Lower Extremity Venous Insufficiency Due to Pelvic Leak Points in Women

■ Claude Francheschi, MD,¹ and Amine Bahnini, MD, Paris, France

INTRODUCTION

Lower extremity venous insufficiency occurring during pregnancy and persisting postpartum is often associated with clinical and duplex ultrasound evidence of varicose veins that may or may not be tributaries of the saphenous vein. These varicosities are different in that they are partially or entirely fed by reflux from the pelvic through leak points. Locating and treatment of these leak points are considered difficult. The purpose of this technical note is to show that anatomical and hemodynamic study of the pelvic venous system provides a theoretical and practical basis for effective diagnosis and treatment.

According to Rouvière¹ there are no valves in any visceral and genital veins in the female pelvis except the right ovarian vein. Since these veins communicate with each other ipsilaterally and with their contralateral counterparts through several vein plexuses (rectal, uterine, vaginal, bladder, and periurethral plexuses) (Fig. 1), they can be considered to form a single incontinent, constitutionally refluxing network. In contrast, the superficial veins (perineal and labial veins) that drain the

region have valves, which prevent refluxing into the superficial vein network.

Pregnancy triggers hemodynamic events that can lead to complex venous disorders involving the pelvic and lower extremities. It submits genital veins to hemodynamic and anatomic changes under the combined effect of three phenomenon. First, low uteroplacental resistances act as true arteriovenous fistulas causing venous dilatation and tortuosity. Second, compression of the iliac veins (especially the left common iliac vein) and the inferior vena cava by the enlarged uterus enhances dilatation of the proximal pelvic veins. Third, high hormonal levels increase venous compliance. Because of the resulting pressure and compliance excesses, varices develop in genital veins and regress only partially after delivery.² In some cases pelvic pressure causes superficial vein incontinence that can be a source of reflux and varices involving the superficial venous network of the perineum, vulva, and lower extremities.³ The causes of venous hypertension in the groin disappear after childbirth but varices regress only partially. Superficial varices may or may not regress within a few weeks depending on their capacity to recover competency.

¹Center for Complex Venous Diseases and Malformations, Saint Joseph Hospital, Paris, France.

²Department of Vascular Surgery, Pitié-Salpêtrière University Hospital, Paris, France.

Correspondence to: Amine Bahnini, MD, Service de Chirurgie Vasculaire, GH Pitié-Salpêtrière, 47/83 Bd de l'Hôpital, 75651, Paris, Cedex 13, France, E-mail: veronique.biberon@psl.ap-hop-paris.fr

Ann Vasc Surg 2005; 19: 1-6
DOI: 10.1007/s10016-004-0180-9
© Annals of Vascular Surgery Inc.
Published online: ■

LEAK POINTS IN THE PELVIS

Definition

Pelvic leak points play the same role as perforating veins feeding superficial veins by reflux. The main leak points are the perineal point (point P) fed by the internal pudendal vein and the inguinal point (point I) fed by the round ligament vein of the uterus. One of these two leak points feeds most vulvar or perineal varices that may extend to the

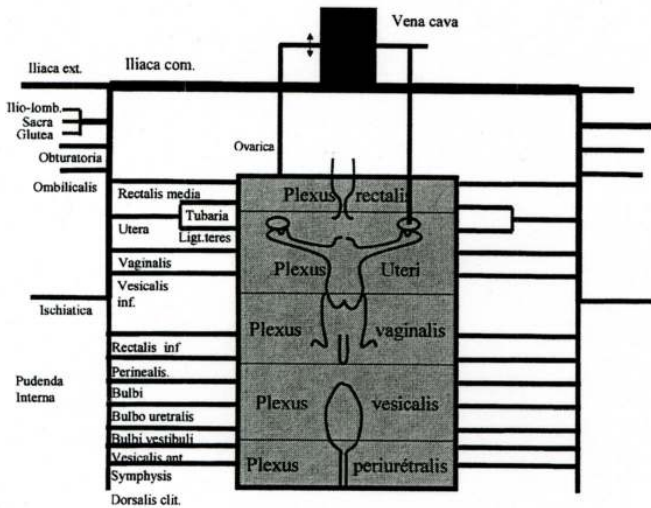


Fig. 1. Anatomofunctional classification of the venous system in the female pelvis. Note that there are many ipsilateral and heterolateral anastomoses between visceral and genital veins as a result of the presence of many intracommunicating plexuses.

superficial veins of the ipsilateral and/or contralateral lower extremity via anastomoses. Involvement of other leak points fed by gluteal, sciatic, or obturator veins is less frequent in association with pregnancy than with congenital malformation and postphlebotic sequelae.

Pelvic varices usually persist after childbirth and are generally well tolerated. They do not cause excess pressure in comparison with nulliparas insofar as incontinence is constitutional. In contrast, parietal pressure is greater because of the increase in lumen diameter in accordance with Laplace's law. Any attempt at neovalvulation or ligation or embolization in the veins composing this single, incontinent network is hemodynamically bound to failure because it will be immediately circumvented and pressure or leakage via points I and/or P will continue unabated. Effective treatment of lower extremity superficial venous reflux of pelvic origin can only be achieved by ligation of the leak points in the same way as is necessary to ligate a refluxing perforating vein or junction. Proximal or distal ligation without ligation of point P and/or point I will be followed by recurrence due to collateral flow (Fig. 2).

Functional Anatomy (Figs. 3 and 4)

Point P. Perineal veins drain the skin of the perineum then receive the anterior and posterior labial veins and pass through the superficial aponeurosis of the perineum (fascia perinalis) by an orifice that we call the perineal point (point P). After crossing point P, the veins ascend with bulbar and cavernous veins to the pudendal vein in the Alcock's canal.

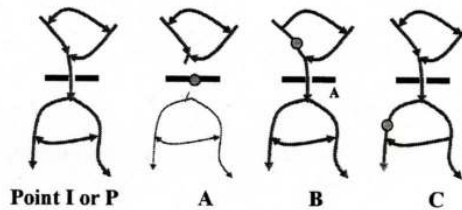


Fig. 2. Ligation of leak points. The perineal and inguinal leak points (points P and I) act as perforating veins. Remote disconnection (B, C) invariably fails either immediately or secondarily because of the presence of many branches and anastomoses.

In case of leakage, reflux follows the same pathway in the opposite direction. Reflux can not only cause dilatation of the labial and perineal veins but also extend to the ipsilateral saphenous network through either perineal-to-labial and perineal-to-external pudendal vein anastomoses or through any other incompetent vein in between. It can also feed a contralateral varicosity through labiolabial and perineoperineal anastomoses. Reflux in the internal pudendal artery is itself fed either actively or potentially by any constitutionally incontinent ipsilateral and contralateral upstream genital, visceral iliac, and ovarian vein and by the inferior vena cava.

Point I. The round ligament vein of the uterus can feed vulvar (labial) and perineal varices and lower extremity varices via residual branches of the Nuck's canal that reflux directly or indirectly to the subcutaneous abdominal, external pudendal, superficial dorsal of the clitoris, and labial veins,

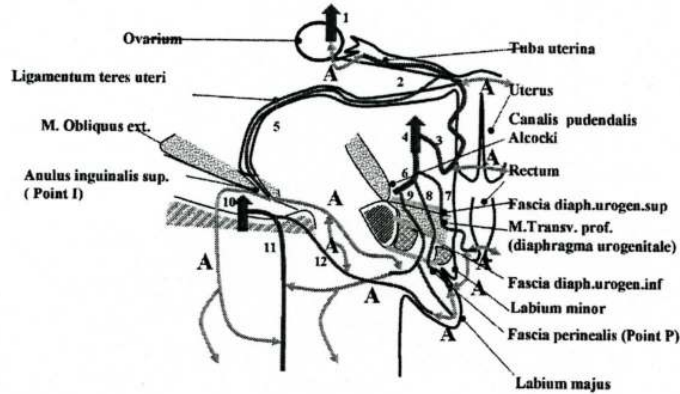


Fig. 3. Frontal view of the pelvis passing through the perineal and inguinal leak points (points P and I). Note the number of anastomoses (A). 1. vena ovarica (ovarian vein); 2. tuba uteri vena (fallopian tube vein); 3. vena uterine (uterine vein); 4. vena iliaca interna (internal iliac vein); 5. ligamentum teres uteri vena (round ligament vein of the uterus); 6. vena pudenda interna (internal pudendal vein); 7. vena rectalis inferior (inferior rectal vein); 8. vena pudenda interna rama (internal pudendal branch vein); 9. vena perinea (perineal vein); 10. vena femoralis (femoral vein); 11. vena saphena magna (greater saphenous vein); 12. vena pudenda externa (external pudendal vein).

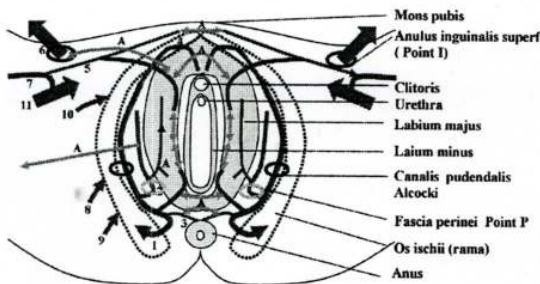


Fig. 4. Perineal view showing the perineal and inguinal leak points (points P and I). Note the number of anastomoses (A). 1. vena pudenda interna (internal pudendal vein); 2. vena perinea (perineal vein); 3. vena rectalis inferior (inferior rectal vein); 4. vena bulbi vestibuli et clitoridi (vein of bulb of vestibule and clitoris); 5. vena pudenda externa (external pudendal vein); 6. ligamentum teres uteri vena (round ligament vein of the uterus); 7. vena saphena magna (great saphenous vein); 8. vena glutea (gluteal vein); 9. vena ischiatica (sciatic vein); 10. vena obturatoria (obturator vein); 11. vena femoralis (femoral vein); 12. vena bulbi vestibuli (vein of bulb of vestibule).

DIAGNOSIS

Clinical data allow diagnosis of vulvar and perineal varices but cannot determine the leak point, since leakage from point I or P leads to the same clinical manifestations. Phlebography does not allow visualization of points P and I because of the presence of numerous vein networks. Only duplex ultrasound (preferably color) allows precise identification of points I and P. With the patient in a standing position, point I can be located approximately 1 to 3 cm above the femoral vein and just medially to the epigastric veins (Fig. 5). To allow detection, reflux must be induced by a Valsalva's maneuver. Point P (Fig. 6) can be located in the gynecologic position transperineally or extravaginally. Reflux can be activated by a Valsalva's maneuver that induces backflow from the Alcock's canal to the perineal and labial veins. Point P is generally located at the junction of the posterior fourth and anterior three-fourths of the labia majorum. The Alcock's canal is located medially to and just above the ischiopubic branch.

TREATMENT

Point P

Ultrasound-guided skin marking is performed with the patient in the gynecological position after shaving the perineum. Perineal varices are labeled as close to point P as possible. Point P is labeled in

then possibly toward varices in the saphenous network. Once again, reflux in the round ligament vein is itself fed either actively or potentially by any constitutionally incontinent ipsilateral and contralateral upstream genital, visceral iliac, and ovarian vein and by the inferior vena cava.

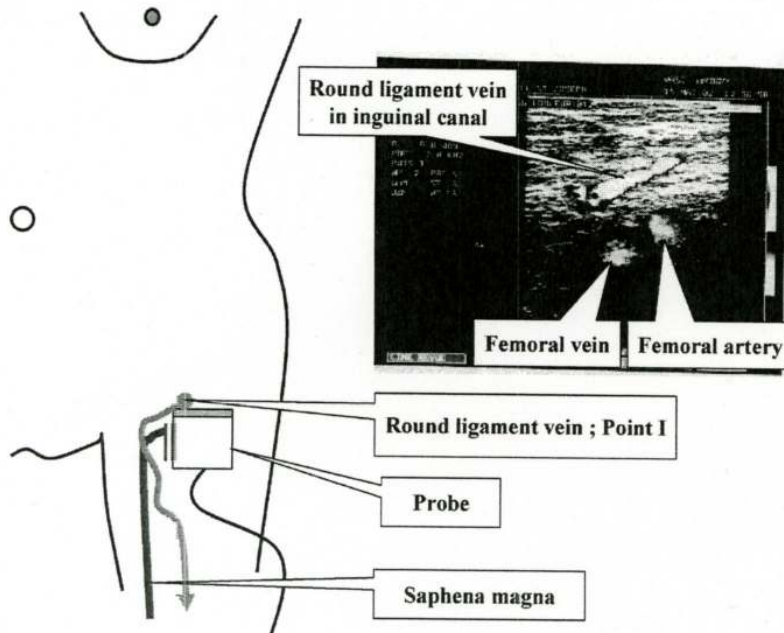


Fig. 5. Ultrasound-guided marking of the inguinal leak point (Point I) in standing position. Reflux induced by Valsalva's maneuver.

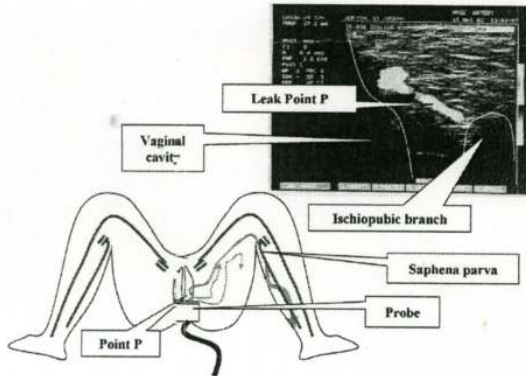


Fig. 6. Ultrasound-guided marking of the perineal leak point (point P) in gynecological position. Reflux induced by Valsalva's maneuver.

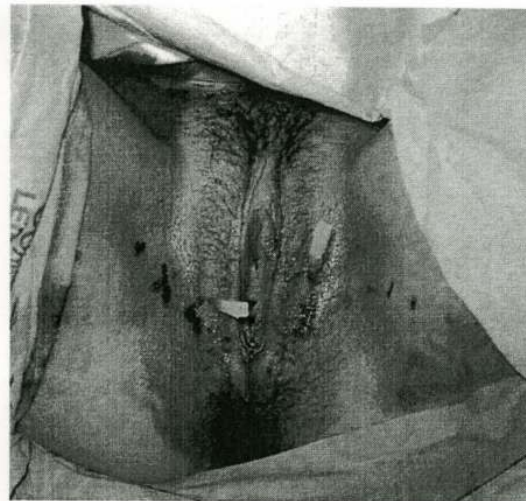

Fig. 7. Ultrasound-guided marking of perineal veins and perineal leak point (point P). Catheters correspond to optional percutaneous marking of point P. Points in the genitocrural fold are marked at the level of point P instead of over point P to avoid incision of the labia majorum.

the genitocrural fold (Fig. 7). Surgical intervention is carried out with the patient in the gynecological position. After local anesthesia of the labeled sites, the perineal varices are exposed by microincisions. Point P is exposed by making a 1- to 2-cm incision in the genitocrural fold at the level of the mark corresponding to point P, i.e., at the posterior fourth of the labia majorum in most cases (Fig. 8).

The varice should be dissected to the orifice in the superficial aponeurosis (point P). After isolation

of the small superficial perineal nerve, the vein can be divided and ligated using nonresorbable suture (polypropylene 4/0). The aponeurotic orifice

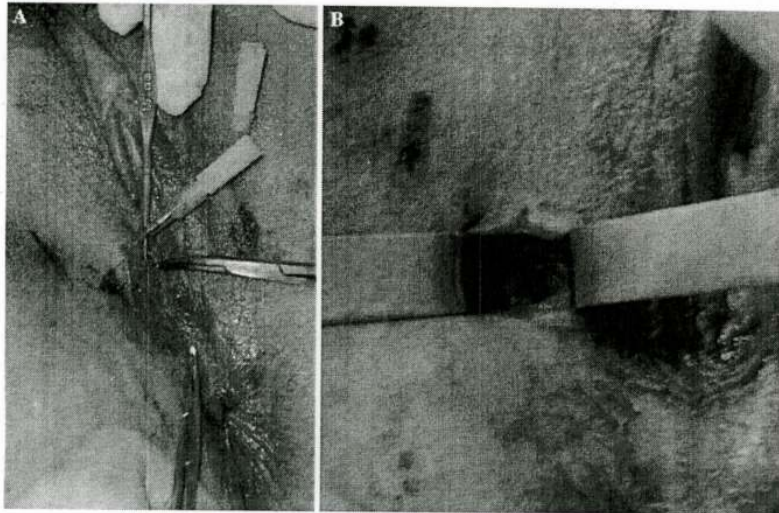


Fig. 8. **A** Surgical exposure of perineal leak point (point P). According to the marking in this case, point P is located at the posterior fourth of the tibia majorum. The perineal vein is dissected up to the fascia then ligated using nonresorbable suture. **B** Visualization of the orifice of point P.

(point P) can then be closed with nonresorbable suture (polypropylene 4/0).

Point I

Ultrasound-guided skin marking around point I (superficial orifice of inguinal canal) is performed with the patient in the dorsal decubitus position. Surgical intervention is carried out in the dorsal decubitus position after local anesthesia of the site. The varice, which is often cavernomatous, is exposed flush with point I. After protection of the small abdominogenital nerve, the vein and the round ligament are divided and ligated using nonresorbable suture (polypropylene 4/0). The superficial inguinal orifice (point I) can then be closed with nonresorbable suture (polypropylene 4/0).

CONCLUSIONS

The early outcome of the procedures that we have performed up to now has been satisfactory. On the basis of this experience we conclude that location and treatment of points I and P allows simple and effective treatment of previously intractable varicosities. More study with a larger patient cohort is needed to confirm this conclusion.

REFERENCES

1. Rouvière H. Anatomie humaine (11th ed.) Vol. II. Paris: Masson, 1974.
2. Rozenblit AM, Ricci ZJ, Tuvia J, Amis ES. Incompetent and dilated ovarian veins: a common CT finding in asymptomatic parous women. *AJR Am J Roentgenol* 2001;176:119-122.
3. Jiang P, Van Ru AM, Christie RA, et al. Non-saphenofemoral venous reflux in the groin in patients with varicose veins. *Eur J Vasc Endovasc Surg* 2001;21:550-557.