

Treatment of Primary Varicose Veins Has Changed with the Introduction of New Techniques

Eric Mowatt-Larssen* and Cynthia K. Shortell*

New technologies have produced a revolution in primary varicose vein treatments. Duplex ultrasound is now used for preoperative diagnosis, postoperative surveillance, and during many procedures. Ultrasound has also altered our understanding of the pathophysiology of chronic venous disease. Laser and radiofrequency saphenous ablations are common. Classic techniques, such as sclerotherapy, high ligation, stripping, and phlebectomy, have been improved. Magnetic resonance venography, computed tomographic venography, and intravascular ultrasound have improved diagnostic capabilities. New strategies like ambulatory selective varices ablation under local anesthesia (ASVAL) and conservative hemodynamic treatment for chronic venous insufficiency (CHIVA) raise important questions about how to manage these patients.

Semin Vasc Surg 25:18-24 © 2012 Published by Elsevier Inc.

PRIMARY VARICOSE VEIN management has undergone a revolution based on technological advances. Duplex ultrasound has impacted almost every facet of phlebology, including preoperative diagnosis, periprocedural monitoring, postoperative surveillance, and even our understanding of the disease process itself. Thermal (laser or radiofrequency) and chemical (sclerotherapy) ablation techniques now far outnumber the surgical procedures of high ligation, stripping, or phlebectomy in the United States.¹ The surgical techniques, however, have evolved as well. Technical advances have also made possible paradigm-challenging advances in our understanding in the natural history of reflux, which have impacted strategies for saphenous, epifascial, and perforator treatment. These technical and intellectual advances have resulted in new certifications with the American Board of Phlebology in 2008 for physicians and Registered Phlebology Sonographer in 2010 for physicians and ultrasonographers.

Ultrasound

Of all the technological changes, the development of venous ultrasound has been the most profound. Ultrasound is now used as the primary diagnostic tool to map the extent of reflux.² It is used routinely during saphenous and perforator

ablation to ensure accurate ablation. It is also used during chemical ablation of epifascial veins if the epifascial veins are large in diameter or near deep veins to ensure accurate placement of the foamed sclerosant.³ After these various treatments, it is used to check for technical success (vein occlusion) and adverse events (eg, heat-induced or deep venous thrombosis).

Besides the dramatic increase in use for procedures, ultrasound techniques have been refined. The reflux study is now performed standing to more closely mimic physiological conditions, when gravity actually causes reflux. Saphenous veins are now defined as running in saphenous sheaths (Fig 1) because these veins are hemodynamically different than the epifascial veins with which they can be confused. Consensus opinion defines reflux as retrograde flow >0.5 seconds (500 ms) in most veins, except 1.0 seconds (1000 ms) in the case of the femoropopliteal system, to account for normal valve closure time.⁴

Ablation Techniques

Thermal ablation has largely replaced surgical high ligation with or without stripping for saphenous veins in the United States (Fig 2).¹ During this procedure, the vein is closed through a process of vein wall and lumen fibrosis.⁵ Reabsorption of the vein occurs over several months in many cases.⁶ Thermal ablation causes less pain and discomfort and reduces convalescence time compared with surgery.² When performed in indicated patients, these procedures are highly technically successful, and improve patient quality of life.⁵

*Duke University Medical Center, Durham, NC.

Address reprint requests to Eric Mowatt-Larssen, Duke Vein Clinic, 3475 Erwin Road, Durham, NC 27705. E-mail: eric.mowatt-larssen@duke.edu

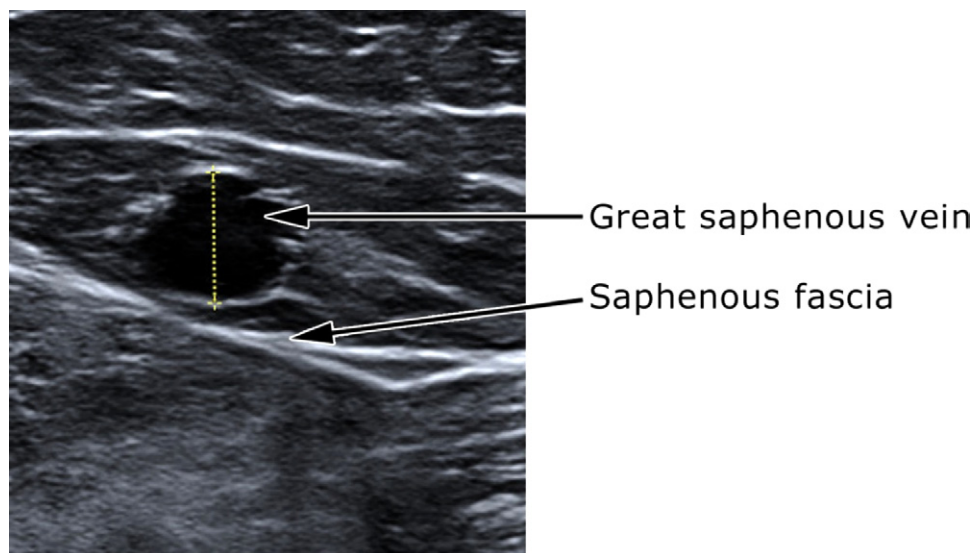


Figure 1 Ultrasound-based definition of saphenous vein. Saphenous veins (such as the great saphenous vein [GSV]) are enclosed above and below the vein in a fascia, visible on cross-sectional ultrasound as an “Egyptian eye” (white lines above and below the GSV), which “blinks” (compresses) with probe pressure. This definition is important due to hemodynamic differences between saphenous and epifascial veins. Photographed by Terry Williams, RVT, and Eric Mowatt-Larssen, MD and adapted from Mowatt-Larssen E, Shortell C, Desai S: Clinical Review of Phlebology and Venous Ultrasound. Durham, NC, Surgisphere Corporation, 2012,³⁸ with permission.

Recent consensus opinion recommends thermal ablation preferentially to surgical or chemical ablation for saphenous veins.² Thermal ablation has also been used successfully in perforator² and saphenous tributary³ ablation as well.

Radiofrequency ablation and laser ablation have similar efficacy and safety.² There has been much debate about the potential importance of laser wavelength, but results seem similar at wavelengths between 810 and 1470 nm. Results depend mostly on energy delivery, good tumescent anesthesia, and proper catheter placement (Fig 3). The choice of radiofrequency or laser energy, or which specific laser wavelength to use, less effect.³

Chemical ablation seemed destined for a minor role in phlebology in 1974, when Hobbs found surgery superior to liquid sclerotherapy in a randomized controlled trial.⁷ The advent of foamed sclerosants, however, transformed chemical ablation because of its increased efficacy. Foam will fill a vein and remain in place unless there is muscle contraction, increasing time of endothelial contact compared with liquid sclerotherapy, which acts as a jet and has a brief endothelial contact time. Additionally, foam is easily visible with ultrasound guidance (Fig 4), facilitating accurate ablation and avoidance of deep vein complications.³ Foam is now commonly used in the treatment of epifascial veins. Foamed sclerosants have also been used with competitive success in treating saphenous veins⁸ and perforator veins.⁹

Chemical ablation has historically been plagued by wide variation in techniques, resulting in a wide range of reported results. This situation is now changing, and techniques are improving rapidly. The optimum sclerosant, sclerosant gas,

sclerosant to gas ratio, safe injection volumes, patient positioning, use of filters to minimize bubble size, among other issues, are still debated.¹⁰

Although endovascular procedure volumes have skyrocketed, surgical procedures have made considerable improvements as well. High ligation with stripping or high ligation alone remain the preferred surgical options for saphenous veins. Most often, high ligation with stripping is performed on the great saphenous vein due to increased efficacy against high ligation alone, and above the knee only to prevent saphenous nerve injury. High ligation alone with a short-length phlebectomy is the usual procedure on the small saphenous vein to prevent sural nerve injury. The procedure is sometimes performed under local anesthesia and with preoperative ultrasound marking.¹¹ A tourniquet can be applied before the procedure to limit blood loss, bruising, and pain. Perforation/invagination stripping instead of acorn use can also limit surgical trauma.¹² Epifascial veins can be treated with ambulatory phlebectomy, which is often performed under local anesthesia and produces small wounds requiring no sutures and results in only small scars (Fig 5).¹³ Powered phlebectomy, using a machine to macerate the varicosities, can save time in the case of numerous varicosities.¹⁴ Subfascial endoscopic perforator surgery remains a viable option to treat pathologic perforator veins.¹⁵

The initial reported results of the new endovascular techniques of thermal and chemical ablation were surrogate outcomes of ultrasound-based vein closure. Clinical scores have since been developed and are now in reasonably common use. CEAP (Clinical, Etiology, Anatomic,

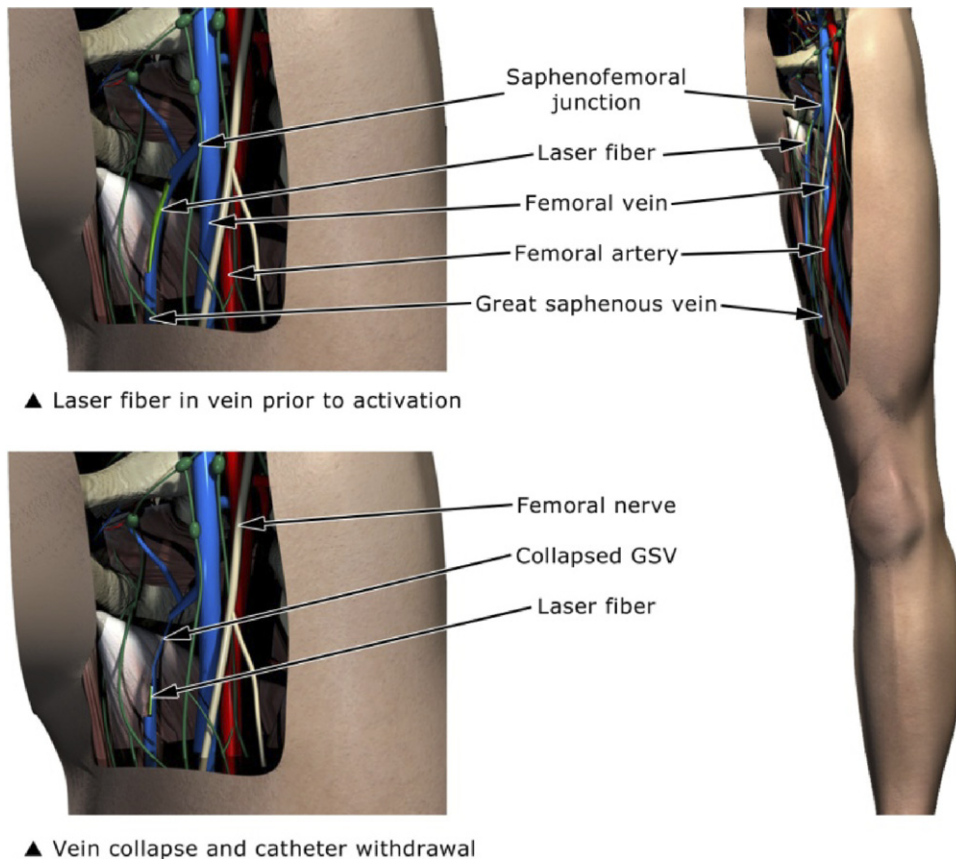


Figure 2 Thermal ablation techniques. Thermal (radiofrequency and laser) ablation techniques are safe and effective and now common for saphenous ablation. GSV, great saphenous vein. Illustrated by Sapan S. Desai, MD, PhD and adapted from Mowatt-Larsen E, Shortell C, Desai S: Clinical Review of Phlebology and Venous Ultrasound. Durham, NC, Surgisphere Corporation, 2012,³⁸ with permission.

Pathophysiologic) score can be used to describe cross-sectional disease severity.¹⁶ The Venous Clinical Severity Score (VCSS) is a newly revised combination of patient-reported and physician-reported disease severity useful longitudinally over time, and can be used to track the results of interventions.¹⁷ Technology has permitted better diagnosis as well. With the improvement in diagnostic

techniques, such as intravascular ultrasound, magnetic resonance venography, and computed tomographic venography, some patients assumed to have primary venous disease are now found to have deep vein issues, and can be managed more effectively. Intravascular ultrasound is more sensitive than venogram at detecting ilio caval venous obstruction, and patients can be effectively treated

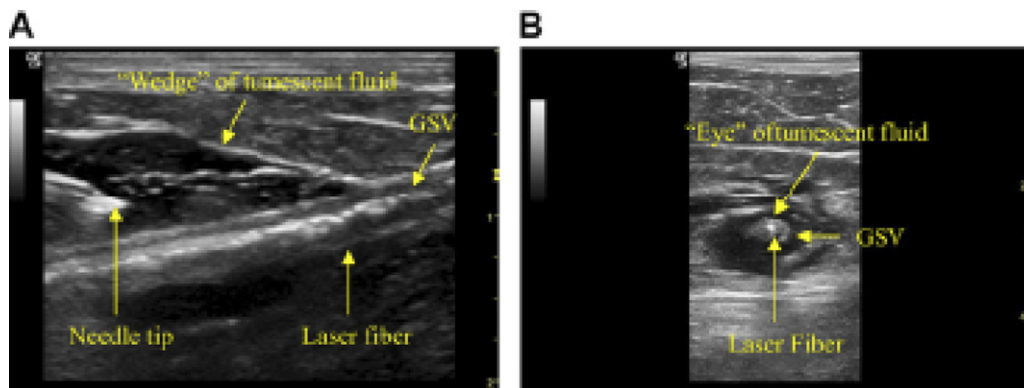


Figure 3 Ultrasound makes tumescent anesthesia possible. (A) Longitudinal and (B) cross-sectional ultrasound view. It is a key factor in safe and effective thermal ablation results. GSV, great saphenous vein. Reprinted from Gibson KD, Ferris BL, Pepper D: Endovenous laser treatment of varicose veins. Surg Clin N Am 87:1253-1265, 2007,³⁹ with permission.

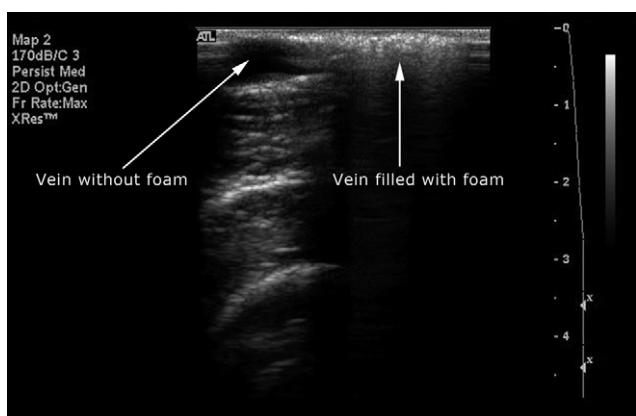


Figure 4 The visibility of foam with ultrasound makes accurate placement possible. Photographed by Terry Williams, RVT, and Eric Mowatt-Larssen, MD, and adapted from Mowatt-Larssen E, Shortell C, Desai S: *Clinical Review of Phlebology and Venous Ultrasound*. Durham, NC, Surgisphere Corporation, 2012,³⁸ with permission.

upon diagnosis with angioplasty and stenting when diagnosed.¹⁸ Pelvic congestion syndrome often presents with proximal medial thigh varicosities, even though the reflux begins in the suprainguinal region, usually the ovarian vein. Ultrasound, magnetic resonance venography, computed tomographic venography, and conventional venography are diagnostic tools to detect pelvic congestion syndrome.²

New Treatment Strategies

In addition to its direct clinical applications, duplex ultrasound has played a key role in understanding the natural history of reflux. In the 19th century, Rima (1836) hypothesized and then Trendelenburg (1890) popularized the idea that reflux progresses from saphenofemoral junction distally down the great saphenous vein over time, defining the saphenous vein as the main treatment target in primary varicose veins.¹⁹ A similar process could explain the saphenopopliteal junction and small saphenous vein. Both longitudinal²⁰ and cross-sectional^{21,22} ultrasound studies now show that reflux can in fact spread proximally over time, and that this process is actually quite common.

If reflux progresses in an anterograde fashion, and reflux can spread from epifascial to saphenous veins, then perhaps treatment of the epifascial veins while the saphenous vein is spared would be effective. Pittaluga and colleagues have presented a retrospective cohort of patients treated with this strategy, called ASVAL (ambulatory selective varices ablation under local anesthesia). Physician judgment is used to decide whether to treat the epifascial veins only, or to also treat the saphenous vein. Patients with primary varicose veins or less severe disease (eg, lower CEAP class or less severe symptoms) have done very well in retrospective analysis of the cohort of patients treated with ASVAL.²³

Importantly, ASVAL treatments result in correction of saphenous reflux with epifascial treatment only in a significant number of patients.²³ Correction of saphenous reflux with epifascial treatment only was also shown using a different strategy in patients with saphenofemoral junction reflux and incompetent varicose tributaries, but a competent saphenous terminal valve.²⁴ These studies raise the possibility that early correction of epifascial reflux before it spreads up the saphenous vein to the terminal valve might, in fact, reverse the disease and prevent the need to treat the saphenous vein at all in many cases.

There has been significant debate over whether concomitant or staged treatments of saphenous and epifascial veins are preferable when both are involved in disease. Not coincidentally, those preferring phlebectomy for epifascial vein management often recommend a concomitant saphenous and epifascial treatment, while those preferring sclerotherapy often recommend a staged management. Concomitant treatments are convenient for the patient and can result in faster symptomatic improvement,²⁵ probably due to the faster removal of refluxing veins. Staged treatments allow epifascial varicosities to become smaller and easier to treat with sclerotherapy.³ Some varicosities disappear after saphenous treatment, thereby preventing unnecessary treatments.²⁶

Perforator vein treatment is a controversial issue. Incompetent perforator veins (IPV) are associated with worse clinical disease based on CEAP class.²⁷ Treatment of IPVs, however, has not been shown to improve clinical outcomes independent of saphenous vein treatment.²⁸ Treatment of IPVs in addition to refluxing saphenous veins did not result in clinical improvement in CEAP class C2 patients compared to saphenous treatment alone.²⁹ Additionally, treatment of the saphenous vein results in correction of perforator incompetence in many patients with a competent deep system.³⁰

Ultrasound and a hemodynamic understanding of IPVs can be helpful. Distal IPVs in the setting of a refluxing saphenous vein likely represent the kind of re-entry perforator analyzed by Bjordal in the 1970s.³¹ Current consensus opinion is to treat IPVs only when the IPV is near an active or healed ulcer, essentially the “ankle blow-out” pathophysiology articulated by Cockett and Jones back in the 1950s.³² Such a strategy leaves out potentially effective treatments for a patient with a proximal IPV acting like an incompetent saphenofemoral junction, or “perforator junction” (Fig 6).

Despite the dramatic improvements in treatment, there is still no cure for primary varicose veins. Recurrence remains a problem. Many of the risk factors for varicose veins, such as aging, genetics, number of pregnancies, and standing occupation, remain difficult or impossible to modify. There is some evidence that leaving a draining deep-saphenous junction (eg, saphenofemoral junction), as is routine in endovascular saphenous ablation, actually reduces the deep-saphenous junction neovascularization, which has plagued high ligation with or without stripping.³³ The saphenous stripping technique has actually been tested with junctional sparing,

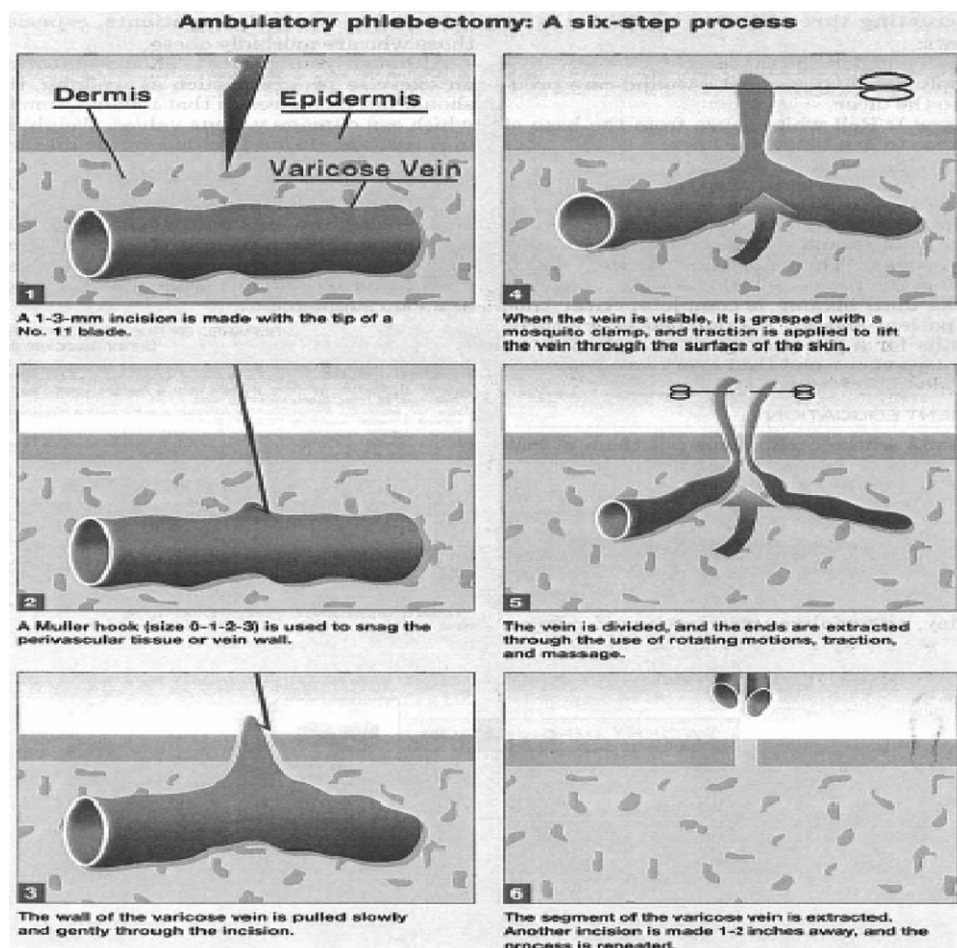


Figure 5 Ambulatory phlebectomy is a minimally invasive technique performed to remove epifascial varicosities. Photographed by Eric Mowatt-Larsen, MD, and adapted from Olivencia JA: Minimally invasive surgery: Ambulatory phlebectomy. *Techniques in Vascular and Interventional Radiology* 6:121-124, 2003⁴⁰ with permission.

similar to the procedure in endovascular ablation, with good results.³⁴

There are now two randomized controlled trials using CHIVA (in French, cure conservatrice et hemodynamique de l'insuffisance veineuse en ambulatoire [conservative hemodynamic treatment for chronic venous insufficiency]), showing a reduction in recurrent varicosities at 5- to 10-year follow-up.^{35,36} In CHIVA, primary varicose vein patients are treated with surgical ligations performed at preoperatively selected points where reflux crosses from deep to saphenous, deep to epifascial, or saphenous to epifascial compartments based on a hemodynamic model.³⁷ Interestingly, the reflux remaining after the CHIVA procedure does cause recurrence. The reduced risk of recurrence from remaining and draining veins, however, more than compensates for the remaining reflux.³⁵ Perhaps the combination of short-segment saphenous thermal ablation (using a perforator-like ablation technique) with the CHIVA strategy would cause even less recurrence than either approach alone. The CHIVA results also suggest that there might be a tradeoff between the patient's symptomatic improvement from the ablation of reflux (or at least its disconnection, as in CHIVA), and the increased risk of

later recurrence from overly aggressive reflux ablation, which can eliminate drainage pathways.

Conclusions

The specialty of phlebology has evolved rapidly, made possible mostly due to better technology. The development of duplex ultrasound has been like the invention of the microscope or telescope in biology or physics, allowing us to see better to monitor venous disease noninvasively in clinical and research uses. Ultrasound is now used preoperatively, intraoperatively, and postoperatively. The endovascular venous ablation techniques of thermal or chemical ablation are safe, effective, and common. Surgical techniques have also made substantial progress. The imaging techniques of intravascular ultrasound, magnetic resonance venography, and computed tomographic venography now allow us to diagnose venous conditions often missed in the past, such as ilioacaval obstruction and pelvic congestion syndrome. Duplex ultrasound has also changed our understanding of the pathophysiology of primary varicose vein disease. Ongoing research suggests that some patients can benefit from epifascial treatment alone, even in the presence of saphenous re-

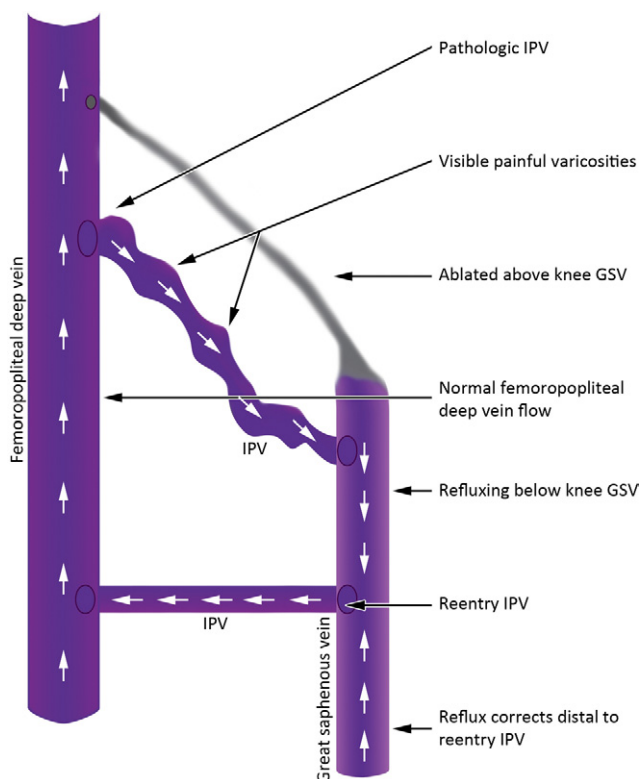


Figure 6 Perforator junction: a proximal perforator can act like a saphenofemoral junction (SFJ). In this reflux map, the proximal reflux begins at a perforator vein acting like an refluxing SFJ. The distal incompetent perforator at the ankle acts like a re-entry perforator, and drains more blood volume than it allows to reflux. GSV, great saphenous vein; IPV, incompetent perforator vein. Illustrated by Sapan S. Desai, MD, PhD, and adapted from Mowatt-Larssen E, Shortell C, Desai S: Clinical Review of Phlebology and Venous Ultrasound. Durham, NC, Surgisphere Corporation, 2012,³⁸ with permission.

flux. The recurrence risk can be reduced by preservation of venous drainage pathways. The future shows tremendous promise.

References

1. Millenium Research Group: US Markets for Varicose Vein Treatment Devices. Toronto, Millenium Research Group, 2009
2. Gloviczki P, Comerota AJ, Dalsing MC, et al: The care of patients with varicose veins and associated chronic venous diseases: clinical practice guidelines of the Society for Vascular Surgery and the American Venous Forum. *J Vasc Surg* 53:25-48S, 2011 (suppl)
3. Mowatt-Larssen E: Management of secondary varicosities. *Semin Vasc Surg* 23:107-112, 2010
4. Cavezzi A, Labropoulos N, Partsch H, et al: Duplex ultrasound investigation of the veins in chronic venous disease of the lower limb—UIP Consensus Document. Part II: Anatomy. *Phlebology* 21:168-179, 2006
5. Mowatt-Larssen E, Shortell C: Truncal vein ablation for laser: radial firing at high wavelength is the key? *J Vasc Endovasc Surg* 17:217-223, 2010
6. Bush RG, Shamma HN, Hammond K: histological changes occurring after endoluminal ablation with two diode lasers (940 and 1319 nm) from acute changes to 4 months. *Lasers Surg Med* 40:676-679, 2008
7. Hobbs JT: Surgery and sclerotherapy in the treatment of varicose veins. *Arch Surg* 190:793-796, 1974
8. Wright D, Gobin JP, Bradbury AW, et al: Varisolve polidocanol micro-foam compared with surgery or sclerotherapy in the management of varicose veins in the presence of trunk vein incompetence: European randomized controlled trial. *Phlebology* 21:180-190, 2006
9. Masuda EM, Kessler DM, Lurie F, et al: The effect of ultrasound-guided sclerotherapy of incompetent perforator veins on venous clinical severity and disability scores. *J Vasc Surg* 43:551-557, 2006
10. Breu FX, Guggenbichler S, Wollmann JC: 2nd European Consensus Meeting on Foam Sclerotherapy 2006. *Vasa* 71:3-29, 2008
11. Rasmussen LH, Bjoern L, Lawaetz M, et al: Randomized trial comparing endovenous laser ablation of the great saphenous vein with high ligation and stripping in patients with varicose veins: short-term results. *J Vasc Surg* 46:308-315, 2007
12. Schelting MR, Wijburg ER, Keulers BJ, et al: Conventional versus invaginated stripping of the great saphenous vein: a randomized, double-blind, controlled clinical trial. *World J Surg* 31:2236-2242, 2007
13. Almeida JI, Raines JK: Ambulatory phlebectomy in the office. *Pers Vasc Surg Endovasc Ther* 20:348-355, 2008
14. Spitz GA, Braxton JM, Bergan JJ: Outpatient varicose vein surgery with transilluminated powered phlebectomy. *J Vasc Surg* 34:547-555, 2000
15. Gloviczki P, Bergan JJ, Rhodes JM, et al: Mid-term results of endoscopic perforator vein interruption for chronic venous insufficiency: lessons learned from the North American subsfascial endoscopic perforator surgery registry. The North American Study Group. *J Vasc Surg* 29:489-502, 1999
16. Eklöf B, Rutherford RB, Bergan JJ, et al: Revision of the CEAP classification for chronic venous disorders: consensus statement. *J Vasc Surg* 40:1248-1252, 2004
17. Vasquez MA, Rabe E, McLafferty RB, et al: Revision of the venous clinical severity score: venous outcomes consensus statement: special communication of the American Venous Forum Ad Hoc Outcomes Working Group. *J Vasc Surg* 52:1387-1396, 2010
18. Neglén P, Hollis KC, Olivier J, et al: Stenting of the venous outflow in chronic venous disease: long-term stent-related outcome, clinical, and hemodynamic result. *J Vasc Surg* 46:979-990, 2007
19. Ricci S: Who discovered saphenous vein incontinence? *Acta Phlebol* 3:95-100, 2003
20. Bernardini EB, De Rango P, Piccioli R, et al: Development of primary superficial venous insufficiency: the ascending theory. observational and hemodynamic data from a 9-year experience. *Ann Vasc Surg* 24:709-720, 2010
21. Labropoulos N, Giannoukas AD, Delis K, et al: Where does venous reflux start? *J Vasc Surg* 26:736-42, 1997
22. Pittaluga P, Chastanet S, Rea B, et al: Classification of saphenous refluxes: implications for treatment. *Phlebology* 23:2-9, 2008
23. Pittaluga P, Chastanet S, Rea B, et al: Midterm results of the surgical treatment of varices by phlebectomy with conservation of a refluxing saphenous vein. *J Vasc Surg* 50:107-118, 2009
24. Pares JO, Juan J, Tellez R, et al: Stripping versus the CHIVA Method: a randomized, controlled trial. *Ann Surg* 251:624-631, 2010
25. Carradice D, Mekako AI, Hatfield J, et al: Randomized clinical trial of concomitant or sequential phlebectomy after endovenous laser therapy for varicose veins. *Br J Surg* 96:369-375, 2009
26. Vasquez MA, Wang J, Mahathanaruk M, et al: The utility of the Venous Clinical Severity Score in 682 limbs treated by radiofrequency saphenous vein ablation. *J Vasc Surg* 45:1008-1015, 2007
27. Labropoulos N: Clinical correlation to various patterns of reflux. *Vasc Endovascular Surg* 31:242-248, 1997
28. O'Donnell TF: The present status of surgery of the superficial venous system in the management of venous ulcer and the evidence for the role of perforator interruption. *J Vasc Surg* 48:1044-1052, 2008
29. Kianifard B, Holdstock J, Allen C, et al: Randomized clinical trial of the effect of adding subsfascial endoscopic perforator surgery to standard great saphenous vein stripping. *Br J Surg* 94:1075-1080, 2007
30. Stuart WP, Adam DJ, Allan PL, et al: Saphenous surgery does not correct perforator incompetence in the presence of deep venous reflux. *J Vasc Surg* 28:834-838, 1998
31. Bjordal RI: Blood circulation in varicose veins of the lower extremities. *Angiology* 23:163-173, 1972

32. Cockett FB, Jones DE: The ankle blow-out syndrome: a new approach to the varicose ulcer problem. *Lancet* 1:17-23, 1953
33. Theivacumar NS, Darwood R, Gough MJ: Neovascularization and recurrence 2 years after varicose vein treatment for sapheno-femoral and great saphenous vein reflux: a comparison of surgery and endovenous laser ablation. *Eur J Vasc Endovasc Surg* 38:203-207, 2009
34. Pittaluga P, Chastanet S, Guex JJ: Great saphenous vein stripping with preservation of sapheno-femoral confluence: hemodynamic and clinical results. *J Vasc Surg* 47:1300-1305, 2008
35. Carandina Carandina S, Mari C, De Palma M, et al: Varicose vein stripping vs haemodynamic correction (CHIVA): a long term randomised trial. *Eur J Vasc Endovasc Surg* 35:230-237, 2008
36. Pares JO, Juan J, Tellez R, et al: Stripping versus the CHIVA method: a randomized, controlled trial. *Ann Surg* 251:624-631, 2010
37. Mowatt-Larssen E, Shortell C: CHIVA. *Semin Vasc Surg* 23:118-122, 2010
38. Mowatt-Larssen E, Shortell C, Desai S (eds): *Clinical Review of Phlebology and Venous Ultrasound*. Durham, NC, Surgisphere Corporation, 2012
39. Gibson KD, Ferris BL, Pepper D: Endovenous laser treatment of varicose veins. *Surg Clin N Am* 87:1253-1265, 2007
40. Olivencia JA: Minimally invasive surgery: Ambulatory phlebectomy. *Techniques in Vascular and Interventional Radiology* 6:121-124, 2003