

The Foot Venous System: Anatomy, Physiology and Relevance to Clinical Practice

STEFANO RICCI, MD, LEO MORO, MD, AND RAFFAELE ANTONELLI INCALZI, MD*

OBJECTIVE This review aims to summarize present knowledge of foot venous return, with a special interest in clinical and research implications.

METHODS It is based on the latest available publications on foot anatomy and hemodynamics.

MATERIALS ANATOMY: Five systems are described: the superficial veins of the sole, the deep veins of the sole (with particular attention to the lateral plantar vein), the superficial dorsal plexus, the marginal veins and the dorsal arch and the perforating system. **The Foot Pump:** The physiology of venous return is briefly described, with an emphasis on the differences between standing and walking and the interplay of the foot and calf venous systems.

RESULTS The hypothesis that the foot and calf venous systems may be in conflict in several clinical conditions (localization of leg ulcers, corona phlebectatica, foot vein dilatation, arteriovenous fistulas of the foot, foot-free bandaging) is presented, briefly discussed, and mechanistically interpreted.

CONCLUSIONS Foot venous return could be more important than is commonly thought. Certain clinical conditions could be explained by a conflict between the mechanisms of the foot pump and the leg pumps most proximal to the foot, rather than by generic pump insufficiency, with possible effects on treatment and compression strategies.

The author has indicated no significant interest with commercial supporters.

Introduction

Blood return from the foot to the heart is commonly thought to be started by the legendary Lejars'¹ sole, a type of foot sponge squeezed by every step, which is actually still under debate. Indeed, little attention has been devoted to the veins of the foot. Surgeons usually perform long stripping, currently applied in few selected cases, starting from the ankle, without involving the foot.² Additionally, ultrasonography does not usually extend its investigation distally, below the malleolus. Anatomists have also been more interested in the foot arteries than in the foot veins, as demonstrated by more detailed descriptions of arteries in anatomical tables. Finally, experts in hemodynamics focus on the calf to explain the limb pump mechanism, neglecting

the foot venous system. However, few but well-conducted classical studies^{3–14} have clarified the anatomical and functional characteristics of foot venous circulation, even though several areas of uncertainty still exist.

First, we review the main concepts of the anatomy and physiology of foot venous return. Second, we attempt to translate these concepts into the observations of clinical interest and to generate working hypotheses for research and daily practice.

Anatomy

Kuster et al.³ provided the most complete description of the foot veins, describing them as divided into five systems:

*All the authors are affiliated with Area di Geriatria, Centro per la Salute dell'Anziano, Universita Campus Bio-Medico di Roma, Roma, Italy

- 1 The superficial veins of the sole, once considered the most important impulse in venous return (Lejars' sole), is a net of tiny veins of limited clinical interest (Figure 1).³
- 2 The deep veins of the sole are the most interesting from a functional point of view and are as follows:

a The *deep plantar venous arch*, which runs from the proximal end of the 1st interosseous space to the base of the fifth metatarsal accompanying the deep plantar arterial arch and receives the deep metatarsal veins and surrounding muscular veins (Figure 2).⁴ The length of this arch measures an average of 9 cm (range 5–14 cm) according to Binns and Pho⁵ and 48 cm according to Corley,⁶ with an average external diameter of 5 cm (Binns and Pho).⁵ Among eight of 10 dissections, the arch was found to be doubled.⁶ Only one valve, proximally located and proximally oriented, has been described.⁵

b The *medial plantar vein*, which is thin and short (5 cm long according to Uhl,⁴ 38 mm long according to Corley⁶ and 12 cm long according to Binns and Pho⁵) and usually doubled, runs along the medial border of the sole, from the medial end of the plantar arch to the medial malleolus to form the posterior tibial veins after confluence with the lateral plantar vein. This vein drains the adjacent

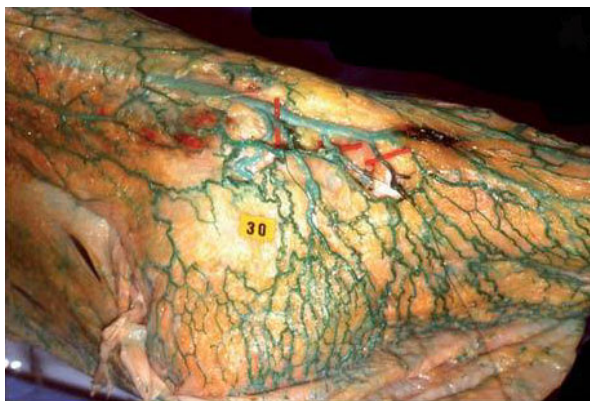


Figure 1. The sole's cutaneous network is composed of a plexus of small veins of 1–2 mm in diameter. Courtesy of Uhl.⁴

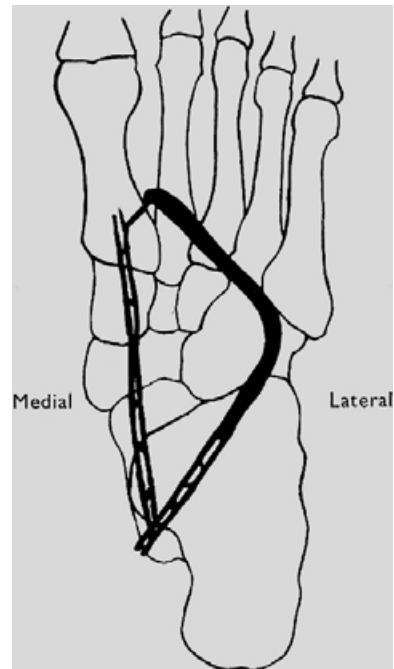


Figure 2. Deep plantar veins projected over the foot bones. Redrawn from Fegan.⁴

muscles: the abductor hallucis, the flexor digitorum brevis and the plantar quadratus muscle. The few valves are proximally oriented.⁵

c The *lateral plantar vein*, which is long (80 mm⁵–84 mm⁶), curved, often doubled and large (2 mm³), with fusiform dilatations (resembling the gastrocnemius sinuses³), is located between the two muscle layers of the sole of the foot (the quadratus plantaris and abductor hallucis). The lateral plantar artery lies between the two stems of this double vein, which are interconnected an average of three times.³ This vessel is in continuity with the lateral end of the plantar venous arch and runs back across the sole, joining the medial vein at the calcaneal confluent and forming the posterior tibial veins. The vein receives blood from the lateral marginal vein, the intermetatarsal veins (in particular, from the 1st and 4th metatarsal interspaces), the calcaneal veins and the veins in the adjacent large plantar muscles. Valves are present and are proximally oriented.⁵

In the deep plantar system, doubled veins have often been observed, with the corresponding artery in between.⁶ The vessels are surrounded by connective tissue; such an arrangement facilitates venous compression by the artery, with localized pumping action.⁷ Furthermore, in a cadaveric dissection, Corley⁶ found repeated evidence of either an evident secondary arch deep in the quadratus plantae or this arch being part of a more complex network of deep interconnections. This phenomenon could represent a potential blood reservoir, explaining the individual differences in venous outflow recorded during muscular activity.⁸

3 The superficial dorsal plexus (Figure 3B) may be clinically important because it is in continuity with the superficial veins of the leg and ankle and

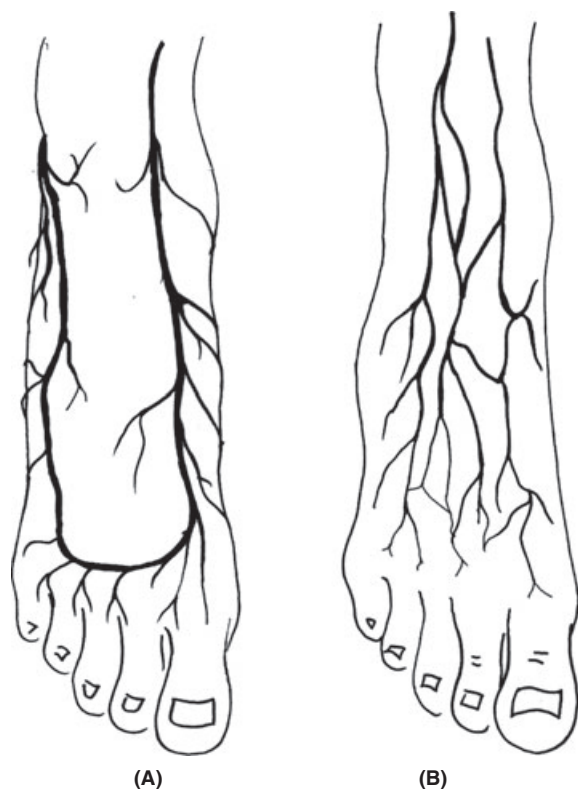


Figure 3. The marginal veins, connected anteriorly by the anterior arch vein (A), are the origin of the two saphenous veins and are similarly situated under the superficial fascia. The superficial network of the dorsum of the foot is in continuity with the superficial network of the anterior leg (B). From Ricci.⁹

may be involved in their varicose dilatation. These veins are very superficial (limited fat layer), clearly visible (aesthetically demanding) and in contiguity with the cutaneous nerves (easily encountered during foot phlebectomies).

4 The marginal veins and the dorsal arch (Figure 3A) are separated from the superficial plexus by a relatively strong connective fascia (corresponding to the fascia covering the great saphenous vein (GSV) and the small saphenous vein throughout the limb); thus, the superficial network runs separately over these veins, forming a distinct layer.^{4,9}

The *dorsal arch* lies over the proximal ends of the metatarsal bones and is the origin of the marginal veins, receiving the dorsal metatarsal veins and several perforating veins.

The *medial marginal vein* arises from the perforator of the 1st metatarsal interspace and is in continuity with the GSV. This vessel receives several perforators from the plantar veins that are important from a functional point of view.

The *lateral marginal vein* ends in the short saphenous vein and receives important perforators from the deep plantar veins.

5 The perforating system is most distinctive system of the foot, as these veins are valveless or contain valves oriented from deep to superficial veins.¹⁰ According to Uhl,⁴ we can consider the following:

- a “The perforator of the 1st metatarsal interspace” is generally of large diameter and valveless and connects the dorsal venous arch with the deep plantar system, thus becoming the true starting point of all of the venous networks in the foot. This perforator accompanies the dorsalis pedis artery.
- b “The medial marginal perforators” open into the medial marginal vein. These perforators are differentiated into plantar (three: the malleolar,

the navicular and the cuneiform) and dorsal (to the anterior tibial veins).

- c “The lateral marginal perforators” are calcaneal and cuboidal and join the lateral marginal vein.

The Foot Pump: Hemodynamic Aspects

Venous blood return to the heart in a standing subject in a dynamic state is driven by multiple separated, but integrated, myofascial compartments acting as muscle pump units¹¹: the foot pump, the distal and proximal calf pumps, the thigh pump and the abdominal pump.

Although the calf pump is the most important, the mechanism of return from the extreme periphery may be worthy of more consideration. According to Browse et al.¹² the force required to overcome the pressure of the column of blood within the venous system of the lower leg exceeds the force generated within the muscular compartments of the calf during motion. According to Gardner and Fox,¹³ the plantar venous plexus could overcome this pressure. Located within the plantar surface of the foot, this plexus is submitted to high-pressure compression during ambulation, possibly constituting a mechanism for driving venous outflow from the leg.¹⁴ The foot pump is in fact activated by compression due to either the body’s weight or the plantar muscles’ contraction during each step. According to the anatomical disposition, the site of the pump may be identified in the lateral plantar veins, and its middle portion is dilated and acts as a “reservoir”³ with a volume of 20–30 mL¹⁵ (Figure 4). The ratio of these veins’ diameter referred to that of the posterior tibial veins is 1.91:1, which creates a bellows-type effect, rapidly increasing the velocity of flow within the posterior tibial vein.¹⁴ The distal part of the pump works as a type of “suction pole”³ coming from the highly vascularized toes and the large metatarsal perforator vein, draining the superficial network of the medial marginal vein. At the calcaneal confluent, the posterior part corresponds to an “ejection pole”,³ emptying directly into the posterior tibial veins.

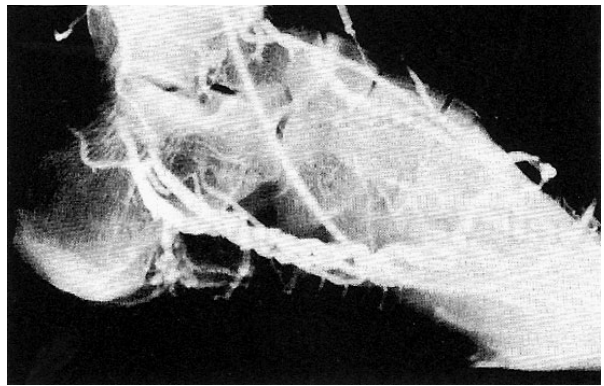


Figure 4. Phlebogram of the lateral plantar veins, with a dilated middle portion acting as a reservoir and emptying into the posterior tibial veins at the calcaneal confluent. Courtesy of Gartner and Fox.¹²

During walking/exercise, the foot is in contact with the ground for 60% of the time and remains off the ground for 40% of the time.¹⁶ The foot architecture is such that weight-bearing occurs nearly entirely on the balls of the toes, the heel and the lateral part of the plantar surface of the foot. The medial part remains pressure free; thus, the plantar veins, which are located here, are protected from direct pressure, except in subjects with flat feet. When the weight is borne, the tarsometatarsal joints are extended, and the foot arch is flattened. Moreover, the plantar veins are forcefully stretched to eject their content. Successively, upon heel strike off, the weight-bearing on the forefoot with dorsiflexion of the toes causes the muscle of the sole to contract, resulting in compression of the pump in the musculotendinous plane.¹³ There is no difference between the venous volume elicited by weight-bearing and by toe curls.⁸ Although it is still unclear why both of these mechanisms produce the same effect and which one is dominant, the two different foot pumps may be active at slightly different points in the stance phase of the gait cycle and are likely to both be active during stance.⁶ The muscle contraction pump is most likely a remnant of a pre-plantigrade phase in ontogenesis (i.e., suspended or immersed life), in the absence of plantar support. Finally, in the suspension phase, filling of the pump is allowed.

Video-phlebography¹¹ has shown that the preferential outflow of the pump is the posterior tibial vein that is in direct continuity. Alternative outflow paths are either the peroneal and anterior tibial veins or the saphenous veins (through the malleolar perforator). The channel with the lower gradient will be favored on any occasion, depending on the muscular activity, temperature, position and/or obstruction.

The GSV may receive blood from the medial marginal vein, the dorsal perforator communicating with the anterior tibial vein and the malleolar perforator vein connected to the calcaneal confluent³ (Figure 5).

Blood from the lateral side of the foot and ankle is drained downward through the intermetatarsal veins that feed the lateral plantar vein, serving as the foot pump “reservoir”. All of these veins are interconnected by the rich net of vessels around the ankle joint. The high number of perforators in the foot and the absence of a unidirectional valvular system are the anatomical basis of the foot pump. However, the deep veins do not empty into the superficial veins of the foot because in weight-bearing, plantar aponeurosis tension closes the perforating veins that

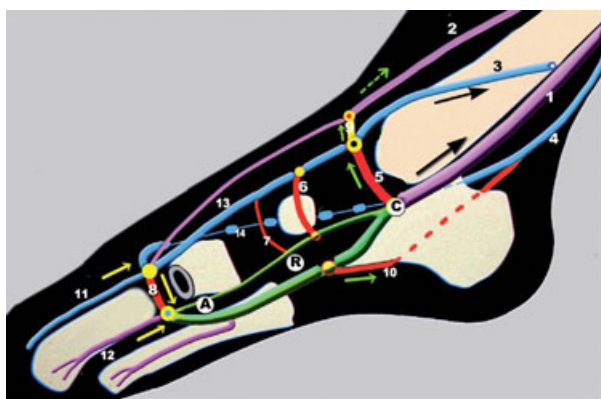


Figure 5. A: Suction pole; R: Reservoir; C: Ejection pole at the calcaneal confluent. 1: Posterior tibial veins; 2: Anterior tibial veins; 3: Great saphenous vein; 4: Short saphenous vein; 5: Malleolar perforator vein; 6: Navicular vein; 7: Cuneiform perforator vein; 8: Perforator vein of the 1st metatarsal interspace; 9: Dorsal perforator vein; 10: Calcaneal perforator vein; 11: Dorsal vein of the hallux, very large; 12: Intermetatarsal vein; 13: Medial marginal vein; 14: Lateral marginal vein. Courtesy of Uhl and Gillot.⁴

pass through.^{13,17} These vessels allow rapid filling of the reservoir that drains the deep and superficial networks and, through alternative outflow channels, allow the ejection of a volume of blood greater than it would be in a closed system.⁴ The saphenous veins of the distal calf can transfer the blood received from the foot pump into the deep veins via the valvulated perforating veins during the diastole (relaxation) of surrounding muscles, when the gradient is favorable.

During ambulation, the foot pump is synchronized with the two calf pumps (distal and proximal) to create a well-defined emptying gradient (Figure 6). In pre-weight-bearing dorsiflexion (A), the distal calf pump is emptied; successive weight-bearing empties the foot pump (B). Final plantar flexion then empties the distal calf pump into the popliteal vein above (C).¹³ From this point onward, the mobilized volume will find further ascending energy to reach the heart in several successive muscular pumping mechanisms, such as popliteal (compression between the heads of the gastrocnemius), sartorius (femoral vein compression during flexion of the hip), quadriceps (deep thigh vein compression during knee extension and hip flexion), hamstring (flexion of the knee), gluteal (extension of the hip), diaphragmatic-thoracic (respiration) and cardiac (suction).¹³

Clinical Considerations

The most active pump in the limbs is the one within the sural and gastrocnemius muscles. These muscles are rich in venous sinuses that are strongly squeezed during the impulse phase of a step (Figure 6C), reaching a pressure exceeding 200 mmHg, with an 80% reduction in calf volume.^{18,19} However, during ambulation, the popliteal venous pressure exceeds the intramuscular pressures in the calf compartments in most of the step phases.¹⁴

At the same time, the plantar plexus seems to be able to overcome the pressure exerted by the column of blood within the deep venous system of the calf.²⁰ Although synchronized with the calf pumps, the

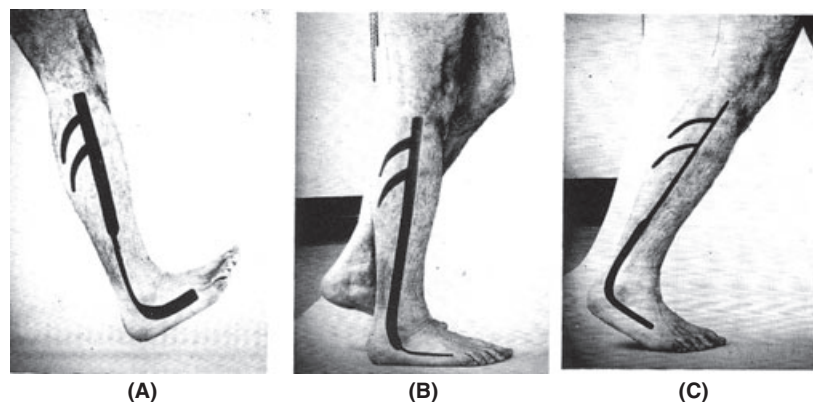


Figure 6. Synchronization of the leg pumps. (A) Dorsiflexion – distal calf pump emptying; (B) Weight-bearing – foot emptying; (C) Plantar flexion – upper calf emptying. Redrawn from Gardner and Fox.¹²

outflow from the foot plexus is independent of calf muscle contraction.¹¹ For these reasons, certain clinical events could be specifically related to the foot pump, particularly when the pump works against a venous overload of the more proximal sections of the limb, as in most chronic venous insufficiency (CVI) situations.²¹

Corona Phlebectatica

This structure has been described as a fan-shaped cluster of small, dilated veins radiating down from the soleal perforator area and over the medial side of the ankle and foot, corresponding to C1 in the CEAP classification.²² The Society for Vascular Surgery and the American Venous Forum consider this phenomenon to be an early sign of advanced venous disease.²³ Corona phlebectatica paraplantar (also known as “malleolar flares” or “ankle flares”) is due to the telangiectatic dilatation of intradermic veins at the medial (more frequently) and lateral sides of the foot. These flares are occasionally a sign of venous hypertension in advanced CVI.²¹ However, the phenomenon may also be present independently in diffuse telangiectasias. The dilatation of the superficial network of the foot skin could be explained as a hypertensive state due to initially normal foot pump activity associated with the events leading to a slowdown of the deep vein blood flow, such as chronic hypomobility (long sitting periods, obesity, laziness, age-related progressive inactivity)

and the use of the wrong type of shoe. The association with CVI, if present, could be casual or, alternatively, the venous hypertension could enhance a preexisting tendency.

Skin Lesions in CVI

Venous ulcers, lipodermatosclerosis and/or pigmentations are typical skin manifestations of venous hypertension in advanced²¹. These symptoms classically appear in the medial supra malleolar area, regularly sparing the foot skin, with limited exceptions. This lesion’s location is most likely due to the relative “hemodynamic weakness” of the supramalleolar area, which contains perforators that act as points of re-entry for superficial reflux but lack a strong pumping mechanism. Indeed, the pressure generated here by the distal calf pump is much lower than the pressure generated distally by the foot pump or proximally by the sural-gastrocnemius pump.

When submitted to re-entry flow from an incompetent saphenous vein system, venous hypertension may be aggravated by the peak pressure generated by the foot pump and may radiate upward with each step. Skin lesions could then be the result of the conflict between the backward venous overflow from distal calf perforators and the active “kicks in” coming from below. A similar effect could result when venous hypertension is due to deep vein

impairment (post-thrombotic syndrome) through the calf perforators (previously called Dodd and Cockett perforators) (Figure 7B).²¹

Varices of the Foot

Varicose veins of the foot have distinctive behavior. Although the most distal part of the leg undergoes the strongest hydrostatic pressure, these varices usually appear late in the progression of the disease. Interestingly, the varices often seem not to be directly involved in the reflux pathways, as if they were “suspended varices” (Figure 7A). Indeed, the most important re-entry perforator/s is/are located more proximally; the dilated veins of the foot are connected to foot perforators and may or may not communicate with the reflux pathway.

These varices might result from the action of the plantar pump “against” a system submitted to hypertension (Figure 7B), and particularly the deep veins, involved in the re-entry of the refluxing volume. The strong foot pump would therefore empty into the more compliant superficial network, developing varicose dilatations of the foot, which

are connected to, but functionally unrelated to, the shunt circuit. Interestingly, foot vein dilatations involve nearly only the superficial network, which is unprotected by the superficial fascia, and spare the saphenous-type veins (the marginal veins) that are sheltered by the superficial fascia, particularly robustly in the foot.^{4,9}

Limb Bandaging without Foot Involvement

Compression of the limb is mandatory after surgery for CVI. This treatment is particularly important when rapid or even immediate post-operative ambulation is requested, such as after ambulatory phlebectomy (AP).

In a consecutive series of over 90 patients submitted to AP, it was observed that the exclusion of the foot from compression therapy/bandaging does not result in distal swelling and congestion.²⁴ This type of approach is possible only in the C2 (of CEAP) stage with a normal deep venous system, without edema, and with active walking. Furthermore, no varices of the foot or the distal limb should be present. Indeed, most patients undergoing AP meet these requisites.

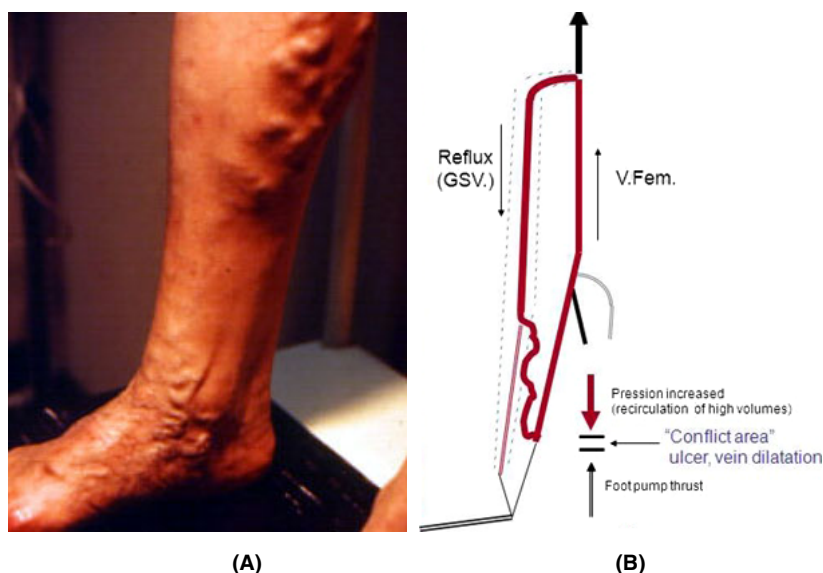


Figure 7. (A) The main re-entry point of the varices of the calf fed by saphenous incompetence is at the distal calf. At the foot varices, dilatation exists, separated from the incompetence course. (B) Action of the plantar pump “against” a system submitted to hypertension (GSV reflux) as a cause of vein dilatation.

In these instances, the compression bandage must be short stretch, acting only during muscle activity and not at rest, and must involve the gastrocnemius area, working as a “Perthes test”. This type of compression allows a patient to wear normal shoes, conceal the surgical procedure and wash the foot, in addition to being more comfortable.

A similar “suspended compression” may be used in the case of inflammatory swelling of the knee joint for decongestive and analgesic purposes, provided that the patient is able to actively walk. Interestingly, an innovative stocking that is more compressive at the upper calf than at the ankle has recently proven to be effective in CVI. This stocking produces “progressive” compression, as opposed to traditional “degressive” compression.²⁵

Arteriovenous Fistulas

In a recent article,²⁶ a method resulting in spontaneous physiological arteriovenous (AV) fistulas between the plantar artery and the dorsal venous arch was suggested. These fistulas are activated when the foot is heated, e.g., by a 38–40°C foot bath for 5 min, and can be visualized by duplex ultrasonography employing a 12 MHz transducer. Arteriovenous shunting potential (Sucquet-Hoyer canals) has been known to exist within the skin of the toes, fingers, nose and ears for thermoregulating purposes.

Although AV fistulas have been reported as potential contributors to the development of thigh and calf varices,²⁷ no information about the clinical relevance of foot AV fistulas is available. The hemodynamic role of these fistulas, particularly in the presence of lower leg or foot varices, are worthy of clarification.

Conclusions

The pathophysiological and clinical conditions collected from the literature and summarized here show that foot venous return is much more than a gait-activated sponge and may be hemodynamically

more important than is usually thought. However, incomplete knowledge of the physiopathology of foot venous return does not allow us to univocally define the relationship between dysfunction and clinical consequences. Certain clinical aspects of venous pathology (ulcer localization, corona phlebectatica, venous dilatations) could be explained by a conflicting mechanism between the foot pump and more proximal pumps, including leg (calf proximal and distal), thigh, diaphragmatic and atrial pumps, rather than by generic pump insufficiency or, more generally, by hypertensive venous conditions (obstruction-reflux). Better knowledge of the anatomy/physiology of the foot venous system could consequently suggest diagnostic protocols (direct eco-Doppler exploration of deep plantar veins, AV shunt comprehension), treatment tactics (avoiding sclerotherapy injections into selected veins that directly communicate with the deep system), surgical strategies (conservative in foot veins involved in the pump function and aggressive in the subcutaneous varicose network) and new compression treatments (“progressive” stockings, postoperative foot-free compression, foot intermittent pneumatic compression devices).

Acknowledgments The authors would like to acknowledge Prof. Roberta Aronica (Roma) for providing editorial help with the manuscript.

References

1. Lejars F. Les veines de la plante du pied. Archives de physiologie. 5^e série. 1890.
2. Myers TT, Cooley JJ. Varicose vein surgery in the management of the postphlebotic limb. Surg Gynecol Obstet 1954;99:733–44.
3. Kuster G, Lofgren EP, Hollinshead WH. Anatomy of the veins of the foot. Surg Gynecol Obstet 1968;127:817.
4. Uhl J-F, Gillot C. Anatomy of the foot venous pump: physiology and influence on chronic venous disease. Phlebology 2012;27:219–30.
5. Binns M, Pho RWH. Anatomy of the ‘venous foot pump’. Injury 1988;19:443–5.
6. Corley GJ. The anatomy and physiology of the venous foot pump. Anat Rec 2010;293:370–8.

7. Benninghoff A, Drenckhahn D. Anatomie (16th ed). Elsevier: Munich, 2004.
8. Broderick BJ, Corley GJ, Quondamatteo F, Breen PP, et al. Venous emptying from the foot. Influences of weight-bearing, toe-curls, electrical stimulation, passive compression and posture. *J Appl Physiol* 2010;109:1045–52.
9. Ricci S. Phlébectomie des varices du pied. *Phlébologie* 2000;53:223–8.
10. Stolic E. Terminology, division and systematic anatomy of the communicating veins of the lower limb. In: May R, Partsch H, Staubead J, editors. *Perforating veins*. Munchen: Urban & Schwarzenberg Ed; 1981. pp. 19–34.
11. Gardner AMN, Fox RH. The return of blood to the heart. John Libbey: London, 1993; pp. 63–5.
12. Browse NR, Burnand KG, Thomas ML. Physiology and functional anatomy. In: Arnold E, editor. *Diseases of the veins: diagnosis and treatment*. London: Hodder and Stoughton; 1988. pp. 53–69.
13. Gardner AMN, Fox RH. The venous system in health and disease. IOS Press: Amsterdam, 2001.
14. White VJ, Katz ML, Cisek P, Kreithen J. Venous outflow of the leg: anatomy and physiologic mechanism of the plantar venous plexus. *J Vasc Surg* 1996;24:819–24.
15. Scurr JH, Coleridge Smith PC. La pompe musculaire du pied importance physiologique et clinique. *Phlébologie* 1993;46:209–16.
16. Murray MP, Drought AB, Kory RC. Walking patterns in normal men. *J Bone Joint Surg A* 1964;46:335–60.
17. Askar O, Aly SA. The veins of the foot. *J Cardiovasc Surg* 1975;16:53–63.
18. Ludbrook J. The musculo-venous pump of the human lower limb. *Am Heart J* 1966;71:635–41.
19. Fronck A. Photoplethysmography in the diagnosis of venous disease. *Dermatol Surg* 1995;21:64–6.
20. Lundeen S, Lundquist K, Cornwall MW, McPoil TG. Plantar pressures during level walking compared to other ambulatory activities. *Foot Ankle Int* 1994;15:324–8.
21. Tibbs DJ. *Varicose veins and related disorders: chap. 4*. Butterworth-Heinemann Ltd: Oxford, 1992.
22. Ruckley CV, Evans CJ, Allan PL, Lee AJ, et al. Chronic venous insufficiency: clinical and duplex correlations. the Edinburgh vein study of venous disorders in the general population. *J Vasc Surg* 2002;36:520–5.
23. Głowiczki P, Comerota AJ, Dalsing MC, Eklof BG, et al. The care of patients with varicose veins and associated chronic venous diseases: clinical practice guidelines of the Society for Vascular Surgery and the American Venous Forum. *J Vasc Surg* 2011;53:2S–48S.
24. Ricci S, Moro L, Trillo L, Antonelli Incalzi R. Foot-sparing postoperative compression bandage: a possible alternative to the traditional bandage. *Phlebology* 2013;28:47–50.
25. Mosti G, Partsch H. Compression stockings with a negative pressure gradient have a more pronounced effect on venous pumping function than graduated elastic compression stockings. *Eur J Vasc Endovasc Surg* 2011;42:261e266.
26. Yoshida Y, Fujita M. Shunt flow of arteriovenous fistulas from plantar artery. *Phlebology* 2011;26:32–4.
27. Haimovici H. Role of precapillary arteriovenous shunting in the pathogenesis of varicose veins and its therapeutic implications. *Surgery* 1987;101:515–22.

Address correspondence and reprint requests to:
Stefano Ricci, MD, Corso Trieste 123 – 00198 Roma,
Italy, or e-mail: varicci@tiscali.it