

Mechanisms of varicose vein formation: valve dysfunction and wall dilation

J D Raffetto* and R A Khalil^{†,‡}

*Division of Vascular Surgery, VA Boston Healthcare System, West Roxbury; [†]Division of Vascular Surgery, Brigham and Women's Hospital, Boston; [‡]Harvard Medical School, Boston, MA, USA

Abstract

Varicose veins are a common venous disease of the lower extremity. Although the mechanisms and determinants in the development of varicosities are not clearly defined, recent clinical studies and basic science research have cast some light on possible mechanisms of the disease. In varicose veins, there are reflux and incompetent valves as well as vein wall dilation. Primary structural changes in the valves may make them 'leaky', with progressive reflux causing secondary changes in the vein wall. Alternatively, or concurrently, the valves may become incompetent secondary to structural abnormalities and focal dilation in vein wall segments near the valve junctions, and the reflux ensues as an epiphenomenon. The increase in venous pressure causes structural and functional changes in the vein wall that leads to further venous dilation. Increase in vein wall tension augments the expression/activity of matrix metalloproteinases (MMPs), which induces degradation of the extracellular matrix proteins and affect the structural integrity of the vein wall. Recent evidence also suggests an effect of MMPs on the endothelium and smooth muscle components of the vein wall and thereby causing changes in the venous constriction/relaxation properties. Endothelial cell injury also triggers leukocyte infiltration, activation and inflammation, which lead to further vein wall damage. Thus, vein wall dilation appears to precede valve dysfunction, and the MMP activation and superimposed inflammation and fibrosis would then lead to chronic and progressive venous insufficiency and varicose vein formation.

Keywords: chronic venous disease; inflammation; matrix metalloproteinases; varicose veins; venous pressure

Introduction

According to the recent clinical, aetiological, anatomical and pathological elements (CEAP) classification, chronic venous disease (CVD) has been classified into seven clinical classes, C0–6, thus defining as follows: C0, no visible sign of venous disease; C1, telangiectasies or reticular veins; C2, varicose veins; C3, oedema; C4a, pigmentation or eczema; C4b, lipodermatosclerosis or atrophie

blanche; C5, healed ulcer; C6, active ulcer. In addition, C4–6 have been designated as chronic venous insufficiency (CVI), reflecting the advanced clinical stage of venous disease.^{1,2}

Varicose veins are a common venous disease that affects over 25 million of the adult population in USA. Varicose veins are superficial vessels in the lower extremity that are abnormally twisted, lengthened and dilated, and often associated with incompetent valves within the vein. In all individuals in the standing position, the column of blood in the venous system reflects a venous pressure at the ankle of 90–100 mmHg.^{3,4} This venous pressure column is transmitted to the vein wall as a significant increase in tension. Despite this significant venous pressure and wall tension, not all individuals develop venous insufficiency and varicose

Correspondence: **Joseph D Raffetto MD**, Division of Vascular Surgery, VA Boston Healthcare System, Surgery 112, 1400 VFW Parkway, West Roxbury, MA 02132, USA.
Email: joseph.raffetto@med.va.gov

Accepted 2 August 2007

veins. How the transmitted hydrostatic pressure incites a stimulus in the venous system of certain individuals to cause varicose veins remains unclear. Several predisposing genetic and environmental factors have been associated with CVD, but the specific mechanisms and determinants in the development of varicosities have not been clearly defined. It is well recognized that, in varicose veins, there is reflux with incompetent valves and vein wall dilation and both leads to CVD. But how do the valves become incompetent? Are there primary changes in the structure of the valves making them 'leaky' with progressive reflux, which then induces changes in the venous wall and result in CVD? Are there structural abnormalities in the vein wall near the valve junctions that become dilated, and then valve reflux occurs as a secondary event (epiphenomenon)? The short answer to these questions is we do not know for sure. It is well recognized that valve reflux and venous wall distension can lead to the other. However, the biophysics/mechanical forces may allow a primary vein wall dilation to expand to the neighbouring valves and cause direct valve distortion, dysfunction and leakage.² On the other hand, a primary valve dysfunction may need to reach a threshold level that causes significant reflux, increased venous hydrostatic pressure and chronic venous hypertension, which may then cause secondary vein wall dilation (Figure 1). Also, there are clinical observations and basic experimental data that may help us understand how the process of varicose veins formation takes place. Recent studies suggest that mechanical stretch/pressure in human tissues leads to the over-expression of matrix metalloproteinases (MMPs) in fibroblasts, endothelial cells and smooth muscle cells (Figure 1).⁵⁻⁷ In addition to their effect on the extracellular matrix (ECM), MMPs may have other effects on the endothelium and smooth muscles. Also, the increased venous hydrostatic pressure may induce endothelial cell permeability/injury, leukocyte infiltration, attachment, and thereby initiating an inflammatory cascade.⁸ Persistent leukocyte infiltration and activation in the venous wall leads to tissue fibrosis, which in the late stage of CVI contributes to wall degeneration, valve degradation and irreversible vein damage.

The objective of this review is to highlight the clinical and experimental evidence and the literature obtained from the National Centres for Biotechnology Information searched under PubMed, with emphasis on the predisposing factors leading to valve dysfunction and wall dilation in the setting

of progressive venous dilation, varicose vein formation and CVI. Because of the critical role of MMPs in venous inflammation, ECM degradation and wall dilation, we will begin the review with a brief description of the MMPs structure and function.

Structure and function of matrix metalloproteinases

MMPs are highly homologous zinc-dependent endopeptidases that belong to a large group of proteases called the metzincins, and are able to cleave most of the constituents of ECM.^{9,10} To date, 26 MMPs have been identified in vertebrates: 23 of them have been found in humans, and at least 14 of them have been identified in vascular tissues (Table 1). MMPs are classified according to their structural components and substrate specificity into five major families: collagenases, gelatinases, stomelysins, matrilysins and membrane-type MMP. Other MMPs may have unique properties and include enamelysins and metalloelastase. The basic MMP structure consists of a prodomain, catalytic domain, hinge region and hemopexin domain. MMPs are produced in a pro-inactive form (proMMP), which are activated by various exogenous and endogenous activators including MMPs themselves. The activity of MMP is further controlled by endogenous tissue inhibitors of MMPs (TIMP 1-4).¹¹

Predisposing factors for chronic venous disease

Predisposing factors such as age and gender could play a role in the development of varicose veins and CVD. In many studies CVD appears to be more prevalent in women.¹² The Framingham Study, found an annual incidence of varicose vein of 2.6% in women and 1.9% in men.¹³ In the well-designed cross-sectional Edinburgh Vein Study that screened 1566 subjects for CVD involved 12 general practices and evaluated patients who were 18-64 years old, and found that women were more likely to report leg symptoms.¹⁴ However, in a follow-up study, the age-adjusted prevalence of truncal varicose veins was 40% in men and 32% in women, and the prevalence of varicose veins and CVD increased with age.¹⁵ Also, by duplex ultrasound evaluation for reflux found CVD in 9.4% of men and 6.6% of women, which rose significantly with age (21.2% in men older than 50, and 12.0% in women older than 50).¹⁶

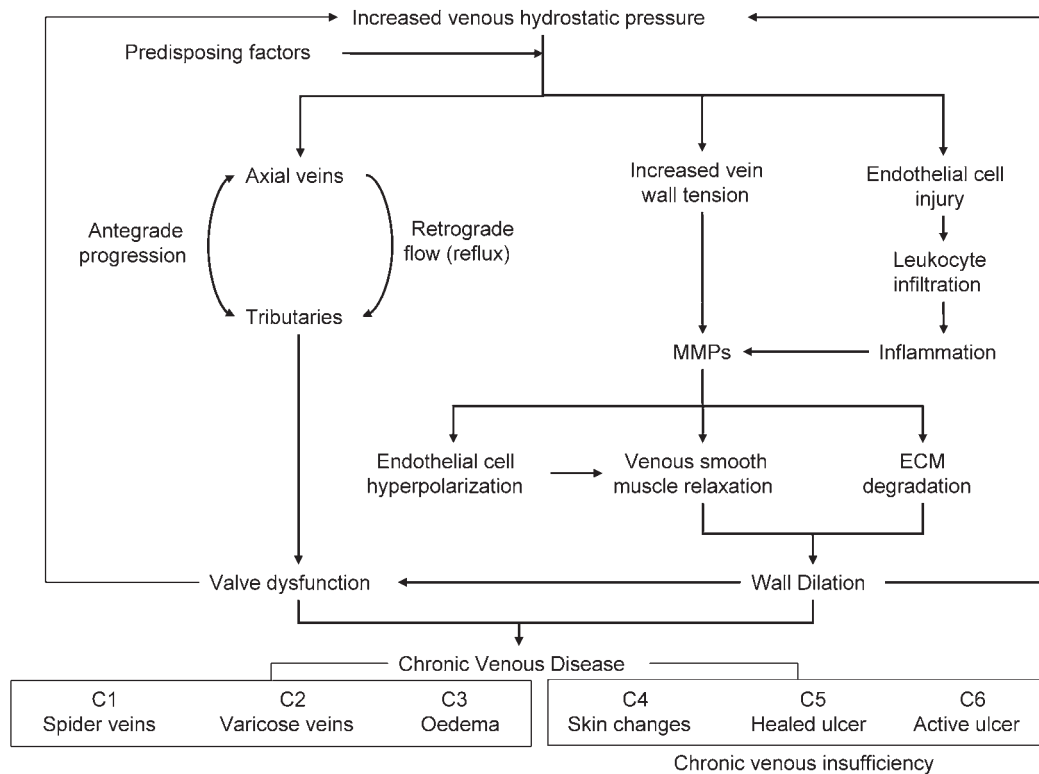


Figure 1 Mechanisms of varicose vein formation. Increased hydrostatic pressure and wall tension in individuals with predisposing risk factors causes matrix metalloproteinases (MMPs) activation and changes in the endothelium and vascular smooth muscle function. In addition, leukocyte wall infiltration and inflammation activates MMPs and leads to extracellular matrix degradation, venous wall weakening and wall/valve fibrosis. Although a possible mechanism may involve primary valve insufficiency in both the axial and tributary veins, this likely represents a secondary event from primary venous wall changes and dilation. Persistent venous wall dilation and valvular dysfunction leads to increased hydrostatic pressure. MMP-mediated vein wall dilation with secondary valve dysfunction leads to chronic venous disease (CVD) and varicose vein formation. The early stages of CVD are maintained within the vasculature leading to clinical sign of varicose veins, while more advanced CVD causes progression of chronic venous insufficiency affecting surrounding tissues and leading to skin changes and ulcer formation

Table 1 Members of the MMP family in vascular tissues

MMP	Other name	Molecular weight (kDa)		Collagen substrate	Other substrates
		Proform	Active		
MMP-1	Collagenase-1	55	45	I, II, III, VII, VIII, X	Aggrecan, Gelatin, MMP-2, -9
MMP-2	Gelatinase-A	72	66	I, II, III, IV, V, VII, X, XI	Aggrecan, Elastin, Fibronectin, Gelatin, Laminin, MMP-9, -13
MMP-3	Stromelysin-1	57	45	II, III, IV, IX, X, XI	Aggrecan, Elastin, Fibronectin, Gelatin, Laminin, MMP-7, -8, -13
MMP-7	Matrilysin-1	28	19	IV, X	Aggrecan, Elastin, Fibronectin, Gelatin, Laminin, MMP-1, -2, -9
MMP-8	Collagenase-2	75	58	I, II, III, V, VII, VIII, X	Aggrecan, Elastin, Fibronectin, Gelatin, Laminin
MMP-9	Gelatinase-B	92	86	IV, V, VII, X, XIV	Aggrecan, Elastin, Fibronectin, Gelatin
MMP-10	Stromelysin-2	57	44	III, IV, V	Aggrecan, Elastin, Fibronectin, Gelatin, Laminin, MMP-1, -8
MMP-11	Stromelysin-3	51	44	None	Aggrecan, Fibronectin, Laminin
MMP-12	Metalloelastase	54	45 and 22	IV	Elastin, Fibronectin, Gelatin, Laminin
MMP-13	Collagenase-3	60	48	I, II, III, IV	Aggrecan, Gelatin
MMP-14	Membrane-Type MT1-MMP	66	56	I, II, III	Aggrecan, Elastin, Fibronectin, Gelatin, Laminin, MMP-2, -13
MMP-15	MT2-MMP	72	50	I	Fibronectin, Gelatin, Laminin, MMP-2
MMP-16	MT3-MMP	64	52	I	MMP-2
MMP-24	MT5-MMP	57	53	None	Fibrin, Gelatin

Other risk factors that could be associated with CVD include pregnancy, oestrogen therapy, obesity, family history of varicose veins, phlebitis and prior leg injury.^{17,18} Evidence for familial hereditary factors may also be important indicating a genetic basis for risk of varicose vein formation.¹⁹ There may also be environmental or behavioural factors associated with CVD such as prolonged standing and perhaps a sitting posture at work.^{18,20}

Although a clear genetic basis for varicose vein formation has not been identified, there have been advances in determining the role of certain genes in CVD. Iron deposition is a known complication of long-standing venous reflux. Studies have quantified the amount of venous reflux and have shown direct correlation with the advanced clinical symptoms of CVI including skin changes and lipodermatosclerosis.²¹ However, iron deposition has also been shown to induce free radical formation, which may cause further tissue injury and thereby lead to more advanced forms of CVI characterized by wound ulceration. One possible mechanism of CVD is iron overload with dermal haemosiderin deposition, free radical formation with tissue injury and progression to skin ulcer formation.^{22,23} Also, factor XIII is an important cross-linking protein that plays a key role during ulcer healing.²⁴ These observations have prompted investigation of whether the genes associated with haemochromatosis and factor XIII had mutations in patients with CVD. Haemochromatosis C282Y (HFE) gene mutation and certain factor XIII V34L gene variants have been demonstrated in patients with CVD and varicose veins, and may have long-term implications for increased risk of more severe forms of CVD (venous skin changes and ulceration), as well as the size of venous ulcers.^{25,26} HFE and FXIII genes were also evaluated in predicting venous ulcer healing following superficial venous surgery in patients with CVD. It was demonstrated that specific FXIII genotypes had favourable ulcer healing rates, while the HFE gene mutation, despite its importance in venous ulcer risk, had no influence on healing time.²⁷

There are several clinical conditions that would support a genetic basis for varicose vein formation. In the congenital Klippel-Trenaunay Syndrome (KTS), the patient presents with varicose veins, limb hypertrophy and dermal capillary haemangiomas (port wine stain). Patients with KTS have congenital venous anomalies in the form of atresia, agenesis of the deep venous system, valvular insufficiency, venous aneurysms and embryonic veins.²⁸ These patients have a significant impairment of venous muscle pump function and valvular compe-

tence, and have advanced symptoms of CVI.²⁹ In the rare primary lymphoedema-distichiasis syndrome, gene mutation in FOXC2 is found and varicose veins are commonly observed as one of its phenotypic features at an early age. These findings have implicated FOXC2 gene in the pathogenesis of varicose vein formation and provided evidence that varicose veins have a heritable element.^{30,31} Also in the CADASIL pedigree with varicose veins, a heterogeneous mutation on the Notch3 gene has been identified, which is thought to lead to degeneration of venous vascular smooth muscle cells.³² In addition, gene expression profiles on varicose veins and control veins have shown upregulation of 82 genes from a microarray of 3063 human cDNAs. Of interest, genes regulating the ECM, cytoskeletal proteins and myofibroblasts production were upregulated in varicose veins.³³ Ehlers-Danlos syndrome comprises more than 10 types of connective tissue disorders with abnormal collagen synthesis. The syndrome is characterized by joint hypermobility, distensible skin, ocular disease, bone deformities and fragility, as well as cardiovascular disorders that render blood vessels and visceral tissue walls fragile and susceptible to rupture. Patients with Ehlers-Danlos syndrome type IV, which predisposes to vascular pathology, may present with varicose veins.^{34,35} We should note that hereditary connective tissue syndromes may not always present with varicose veins. In effect, Marfan syndrome is a connective tissue autosomal dominant disorder that carries a mutation in the FBN1 gene which codes for fibrillin-1, an essential protein in elastic fibre synthesis.³⁶ Marfan syndrome mainly affects the aorta and heart valves, and unlike Ehlers-Danlos, is not associated with the development of varicose veins.

Supporting a genetic basis in the risk for development of CVD is the interesting observation that varicose vein formation is not just a local phenomenon, but may affect other tissues and cells in the body in a systemic fashion. Studies have evaluated cultured dermal fibroblasts for collagen abnormalities, to determine if the phenotypic changes observed in venous smooth muscle cells of patients with varicose veins are also present in their dermal fibroblasts. The dermal fibroblast like that of smooth muscle cells cultured from varicose veins, had increased synthesis of type I collagen, but a decrease in the synthesis of type III collagen despite normal transcript production. The significance is that varicose veins patients have a systemic problem with collagen production that affect various tissues, and likely involve post-translational inhibition of type III collagen production. These alterations in collagen synthesis

and the appropriate ratios of collagen (type I and type III) may have an effect on the early changes in the vein wall leading to structural weakness, dilation and varicose vein formation. Also, among the various MMPs evaluated, proMMP-2 was increased in dermal fibroblasts cultured from patients with venous disease. It was concluded that the synthesis of collagen type III is dysregulated in dermal fibroblasts and is comparable to the observations of smooth muscle cells derived from patients with varicose veins, suggesting a systemic alteration in tissue remodelling.³⁷ Type III collagen is important for blood vessels elasticity and distensibility. The abnormal production of type III collagen in both smooth muscle cells cultured from varicose veins and fibroblasts cultured from dermal biopsies of patients with CVD raises the possibility that varicose veins pathology may arise from abnormal matrix collagen deposition. Furthermore, to identify factors involved in the lack of distensibility in varicose veins, a study evaluated the content of hydroxyproline and quantified collagen types I, III and V. It was found that in both smooth muscle cells and fibroblast of patients with varicose veins when compared with control, there was an increase in hydroxyproline content, indicating increased collagen; however, the proportion of collagen type III was significantly reduced despite normal mRNA transcript. These data offered an explanation for the loss of distensibility in varicose veins and suggested that the defect is generalized, supporting a genetic basis for the alterations in varicose vein patients.³⁸

Evidence for a role of primary valve dysfunction

Valve dysfunction with reflux (retrograde flow) is an important factor that leads to progressive venous insufficiency (Figure 1). Pathologic reflux in the venous system may occur in the superficial truncal (great saphenous vein, small saphenous vein), named tributary veins, saphenofemoral and saphenopopliteal junctions, deep venous system and perforator veins. The duration of retrograde flow across a diseased valve has been studied and reflux duration >0.5 s is considered abnormal in superficial veins, deep femoral and calf veins, while reflux duration >1 s is considered significant in femoropopliteal veins.³⁹ Reflux may also occur in the venous tributaries in the absence of any axial reflux in the truncal, deep or perforator veins. Several studies illustrate these points. In a recent study, three groups of age-/sex-matched subjects (asymptomatic; prominent but non-varicose veins;

and patients with varicose veins) were evaluated by colour flow Duplex ultrasound (CFDUS). The prevalence of reflux was 14% in the asymptomatic group; 77% in the prominent but non-varicose veins group; and 87% in the varicose vein group. For the entire cohort, 80% of reflux was confined to the superficial veins. Multisegment reflux was highest in the varicose vein group (95%). It was concluded that primary venous reflux in both superficial and deep veins of the lower limb can take place in an ascending fashion (not retrograde), and importantly the process can be local and segmental.⁴⁰

In a study to further define reflux in non-truncal (non-axial) superficial venous tributaries, 62 patients (84 limbs) with signs and symptoms of CVD, but with no evidence of reflux in truncal saphenous vein or deep veins, perforators or muscular veins, or superficial or deep venous thrombosis, were evaluated with CFDUS and compared with consecutive cases of patients with truncal reflux. In this cohort, the prevalence of tributary reflux was 9.7% (84/860 limbs), and of all tributaries studied 19.9% had reflux. The most common tributaries with reflux were in communication with the greater saphenous vein (65%), lesser saphenous vein (19%) or with both (7%). This study concluded that reflux confined to the superficial tributaries occurs throughout the limb, and importantly, tributary reflux can develop in the absence of reflux in truncal superficial or deep veins or perforator veins.⁴¹ The study also raised two fundamental questions: (1) what leads to tributary reflux without the presence of axial and retrograde insufficiency; (2) if tributaries or superficial venous segments with reflux are left untreated, do they lead to new or extension of reflux in their communicating superficial (i.e. greater and lesser saphenous) or perforator veins? In a recent study involving 90 patients (116 limbs) with CVD that had delayed surgery and two separate CFDUS of the index limb at the same institution, the reflux pattern was unchanged in 73.3% of limbs, but in 11.2% of limbs there was clinical progression and 26.7% had CFDUS progression. The progression was most common in the great saphenous vein and tributaries followed by perforators. Extension of pre-existing reflux was found in 14.7% of limbs and new reflux in 12.1% of limbs. This study concluded that anatomic extension of reflux is frequent and progression is commonly seen after six months from the initial Duplex ultrasound.⁴²

In support of the concept that venous insufficiency can occur in an ascending (antegrade)

progression, a study evaluated the pattern of superficial venous reflux in two distinct groups: 82 patients aged <30 years and 183 patients aged >60 years. In the <30-year-old group, limb reflux was present in tributaries (25%), non-saphenous superficial veins (36%) and in saphenous vein (39%). In the >60-year-old group, reflux in the saphenous vein was more common (62%) and reflux in the tributaries was frequently associated with reflux in the saphenous vein. It was concluded that the presence of saphenous vein reflux is not required for primary varicose vein pathology to occur. Also, the different patterns observed in younger vs. older patients raise the interesting hypothesis that CVD may progress in an antegrade fashion, starting in the tributaries and affecting the saphenous vein (Figure 1).⁴³ Thus, CVD may begin in essentially any vein segment of the limb and can progress to affect other tributaries, superficial and perforator veins, as well as have an ascending and segmental pattern that does not need a retrograde axial reflux to cause CVD.

Evidence for a role of secondary valve dysfunction

The observations that venous reflux occurs both in segmental as well as in an ascending fashion suggest that changes in the vein wall may take place before valve dysfunction. The question then is, what local factors in the vein wall would cause the secondary segmental reflux and valve dysfunction. Studies have evaluated segments of varicose and non-varicose veins for possible changes in the vein wall. In an earlier report, the collagen and elastin content of non-thrombophlebitic greater saphenous varicose vein and saphenous vein proximal to varices was compared with normal saphenous veins. The study found an increase in collagen, a significant decrease in elastin and increased collagen:elastin ratio in both varicose veins and competent saphenous vein segments in proximity to varicosities compared with normal saphenous vein. Gelatin zymography and elastase activity did not show any quantitative differences. It was concluded that in varicose veins and saphenous vein with varices, there is an imbalance in connective tissue matrix, connective tissue changes occur prior to valve insufficiency, and increases in proteolytic activity and matrix degradation are not essential for varicose vein formation.⁴⁴ In support of this study, evaluation of the vein segment at the saphenofemoral junction in patients with varicose veins compared with saphenofemoral vein from

bypass patients demonstrated that MMPs activity was unchanged compared with that of control, with most of the MMPs located in the adventitia, and the content of MMP-2 was decreased while the content of tissue inhibitor of metalloproteinase-1 (TIMP-1) was increased. The authors concluded that structural wall changes and varicose vein formation may occur despite a decrease in proteolytic activity in the vein wall.⁴⁵ Another study investigated the ratio of TIMP-1/MMP-2 and found a three-fold ratio increase in varicose veins compared with normal veins. It was concluded that proteolytic inhibition and ECM accumulation may account for the pathogenesis of varicose veins.⁴⁶ These studies highlight several important points in varicose vein formation: (1) imbalance of connective tissue matrix (collagen: elastin); (2) imbalance of proteolytic tissue degradation; (3) changes in the vein wall connective tissue structure prior to valve insufficiency; (4) proteolytic activity and matrix degradation are not necessary for varicose vein formation. These studies also raise the question of what role do MMPs have in varicose vein formation if not degradation of ECM? MMPs may have different effects on other venous cell types in the early stages of varicose vein formation, in addition to their proteolytic effects on the ECM in the late stages of CVD.

It is apparent that retrograde flow in a venous segment with an incompetent valve can lead to venous hypertension and CVD. It is also likely that changes in the vein wall may affect the venous valve and lead to the clinically observed CFDUS characteristics of reflux (increased duration of retrograde flow). An interesting report evaluated segments of varicose veins in patients using Duplex ultrasound of the greater saphenous vein. The saphenous vein segments had a dilated varicosity that was proximal to a competent venous valve and adjacent to a normal appearing distal vein segment. The study evaluated rigidity, matrix fibres and elastin in the varicose vein and compared it with that of the continuous normal vein. It was demonstrated that the rigidity was the same in both the varicose vein and normal vein, and both vein segments had increased matrix fibres and fragmented elastin. It was concluded that the role of venous valve pathology in varicose veins is secondary to the vein wall changes.⁴⁷ Other studies evaluated the matrix proteins in the vein wall of varicose veins in 372 specimens (17 patients), as compared with normal control veins in 36 specimens (six patients), and took into account the valve-oriented sites as well as the location of vein for comparison. The varicose veins demonstrated a significant

increase in wall matrix proteins that included collagen, laminin and tenascin, and nearly significant fibronectin increase. Importantly, in varicose vein patients, normal appearing segments of vein just inferior to the varicose vein had the same biochemical profile as that of the adjacent varicose vein.⁴⁸ This study provided further evidence that alterations in the vein wall precede changes in the venous valve during varicose vein formation.

Evidence for a role of vein wall dilation

Increased venous hydrostatic pressure could cause endothelial cell damage and leukocyte infiltration (Figure 1), suggesting the involvement of an inflammatory process. However, significant inflammation likely occurs at a later stage of the disease and is preceded by other actions on the endothelium and smooth muscle. Initial increases in wall tension may cause increases in MMPs expression/activity with effects on different wall structures and cell types, including the ECM, fibroblasts, vascular smooth muscle and endothelial cells. In the subsequent sections, we will discuss the role of inflammation followed by the role of MMPs in the pathogenesis of wall dilation and varicose vein formation, and also include studies evaluating apoptosis and how it influences the vein pathology.

Evidence for role of inflammation

The role of leukocyte interaction with the endothelium and progression to inflammation has been studied in varicose vein pathophysiology. Leukocytes are present throughout the circulation and studies have demonstrated fewer leukocytes leaving the extremities of patients with CVD, especially in advanced stages of CVI.⁴⁹ In other studies, venous hypertension resulted in sequestration of activated neutrophils and monocytes in the microcirculation, which persisted despite removal of venous hypertension, indicating leukocyte adhesion to the endothelium.⁵⁰ In an interesting study, plasma collected from patients with CVD caused significant granulocyte activation, which was more prominent in advanced stages of CVI. In addition, there was a greater hydrogen peroxide production from patients' plasma-activated granulocyte than control plasma.⁵¹ These data suggested the presence of a circulating activating factor in the plasma of patients with CVD (circulating CVD factor), that may be important in the

pathophysiology of CVD. Another study found that regardless of the stage of CVD, blood collected from the affected limbs of patients had elevated aggregation of platelets and monocytes when treated with agonists, and overexpression of monocyte activation marker (CD11b) than control subjects.⁵² Also, studies in human saphenous vein specimens from patients with CVD have demonstrated an increased monocytes/macrophage infiltration in the venous wall and valves. Elevated intercellular adhesion molecule-1 (activation of leukocytes to adhere to the endothelium) was detected in CVD specimens, however other cytokines were not.⁵³ There is clinical evidence that certain pharmacological agents such as flavonoids, which affect leukocytes and endothelium by modifying the degree of inflammation and reducing oedema, may have the potential to improve the symptoms associated with CVD. The micronized purified flavonoid fraction, Daflon has been shown to reduce oedema-related symptoms when used either as primary treatment or in conjunction with surgical therapy for CVD.^{54,55} Horse chestnut seed extract, which is rich in flavones, has been found to be as effective in the short-term in reducing leg oedema and pain from CVD, and may also work by increasing venous tone in the dilated varicose vein.⁵⁶ In addition to human studies, a rat model consisting of venous hypertension produced by a femoral arterio-venous (AV) fistula has been used to study the effects of treatment with flavonoids. Untreated veins developed venous hypertension with reflux and morphological changes in the vein wall and valve. In contrast, veins treated with flavonoid had reduced physiological and anatomical changes in response to venous hypertension.⁵⁷

Matrix metalloproteinases and extracellular matrix degradation

A possible explanation for venous dilation and tortuosity may be from the influences of MMPs and their inhibitors (TIMPs), which lead to venous wall remodelling and subsequent dilatation and valve incompetence. Several studies have evaluated the content and activity of MMPs in human varicose veins as well as circulating MMPs in varicose vein patients. To demonstrate that MMPs were induced by postural changes in patients with varicose veins, a study sampled blood from the brachial vein and lower extremity varicose vein in erect patients following 30 min of stasis. It was found that there was an abundant increase of pro-MMP-9 in the plasma of sampled blood from

the varicose vein when compared with arm vein. Also, the proteolytic activity was associated with increased levels of endothelial membrane intercellular adhesion molecule-1 (marker for activation of leukocytes to adhere to the endothelium), vascular cell adhesion molecule-1, angiotensin-converting enzyme and L-selectins indicating endothelial cell and polymorphonuclear cell activation and enzymatic granule release in varicose veins during periods of stasis.⁵⁸ This study provided evidence that MMPs are important proteolytic enzymes in patients with CVD, which are involved in the interaction occurring between leukocytes and the endothelium in the varicose veins.

Several studies have specifically examined various MMPs in varicose veins. A recent study examining MMP-1, MMP-3, MMP-13 in the proximal and distal vein segments in patients with CVD vs. normal control veins, demonstrated that transcriptional mRNA for MMP-1 or MMP-13 was neither different in varicose vs. control veins nor in proximal vs. distal varicose segments. MMP-3 was not amplified in any vein segment studied. However, the protein expression of MMP-1 was elevated in varicose veins when compared with controls. In addition, regional variations of MMP-1 and MMP-13 expression were significantly increased in proximal vs. distal varicose segments. This study supported that the expression of MMPs is increased in varicose veins and that their post-transcriptional modification may explain variations in varicose vein location.⁵⁹ Other studies have provided immunohistochemical evidence for variations of MMPs localization in the intima, media and adventitia. Varicose veins have increased distribution of MMP-1 in all layers, while in normal veins MMP-1 is localized in the endothelium and adventitia. MMP-9 was found throughout the venous wall in both normal and varicose veins, with varicose veins expressing increased levels in the smooth muscle layer. Interestingly, TIMPs were not present in any vein examined.⁶⁰ In another study, MMP-9 immunopositive staining was increased in smooth muscle cells of varicose veins, but not in control veins.⁶¹ These findings, although not causative, suggest that MMPs may affect all layers of the venous wall including the ECM structure leading to venous wall degradation and varicose vein formation.

Of interest is whether varicose veins with concomitant thrombophlebitis have variations in MMPs expression compared with varicose veins. In a recent study evaluating MMP-1, MMP-2, MMP-3 and MMP-9 activity, it was found that thrombophlebitic varicose veins had elevated content of MMPs in

the vein wall, with increased gelatinase and MMP-1 activity. Varicose veins had increased activity of MMP-2. It was concluded that the wall of varicose veins, especially those affected with thrombophlebitis, have extensive alterations in content and activity of MMPs that may lead to remodelling and influence venous wall mechanical properties.⁶²

Experimental studies in animal models have helped clarify the role of MMPs as well as the venous wall and valve changes. There are two *in vivo* animal models that have investigated the effect of acute and chronic venous hypertension on molecular changes of the vein wall and valve function. By creating a femoral artery and vein AV fistula, an acute rat model of venous hypertension evaluated valvular changes and vein wall biochemical characteristics. At three weeks, three of four rats had demonstrable venous reflux and increased venous pressure compared with the contralateral control femoral vein. The pressurized veins were dilated and the valve leaflets length and width were reduced. There was a significant inflammatory response represented by leukocytes infiltrating the entire vein wall, and upregulation of P-selectin and intercellular adhesion molecules. There were no differences in MMP-2 or MMP-9 at three weeks, and interestingly, the number of apoptotic cells in the vein wall and valves was increased.⁶³ A subsequent study evaluated both acute and chronic venous hypertension in the femoral vein of 60 rats by the same methodology. The findings were an increased pressure in the femoral vein with progressive reflux at 42 days post-AV fistula formation. The valves distal to the fistula demonstrated increased diameter, decreased height and valve fibrosis in the media and adventitia. Of interest, valve obliteration was observed and MMP-2 and MMP-9 were significantly elevated after 21 and 42 days of venous hypertension.⁶⁴ These studies demonstrated the feasibility of a rat model of venous hypertension as well as significant endothelial, biochemical and valve structure changes of inflammation and fibrosis in this model. The presence of MMP-2 and -9 in the venous wall with valvular destruction raises the possibility of MMPs effects on the pathogenesis of varicose vein formation. However, only proximal segments of veins were analysed, and whether the venous changes are a result of venous hypertension, venous arterialization or a combination will require further work to evaluate if these venous abnormalities are transmitted to distal segments of the axial veins as observed in human CVD pathology. Also, an increase in apoptosis in this model is not a

feature of human varicose veins, and raises the possibility of differences between venous-induced injury when compared with that resulting from adaptation to an AV fistula.

Smooth muscle cell apoptosis

Apoptosis involves cell suicide in response to intrinsic signals (mitochondrial pathway) or extrinsic stimuli (death receptor pathway, membrane pathway) in order to maintain homeostasis of the organism. In normal cells, the mitochondria express the bcl-2 protein on their surface that is bound to Apaf-1 (apoptotic protease activating factor 1). Internal damage of a cell by reactive oxygen species, drugs, toxins or radiation leads to Apaf-1 dissociation with concomitant Bax (pore former) protein to enter the mitochondria with resultant cytochrome *c* egression in the cytosol. Cytochrome *c* and Apaf-1 bind to caspase 9 (cysteine-specific proteinase, cleave at specific aspartic acid residues) forming an apoptosome that activates other caspases, which digest structural proteins and cleave chromosomal DNA and thereby causing DNA fragmentation. In the extrinsic pathway, the events which commit a cell to either a path of apoptosis or necrotic cell death after a specific stimulus, is dictated in the former and not the latter by the activation of the central cell death signal via a specific set of surface death receptors that form a specific death domain effector and activate caspase 8. The specific inducers of apoptosis include tumour necrosis factor, neurotransmitters, growth factor withdrawal, IL-2 withdrawal, Fas ligands (expressed on cytotoxic T lymphocytes), while reactive oxygen metabolites, viral infection, chemotherapeutic drugs, radiation (UV and gamma) and toxins can affect both the intrinsic and extrinsic pathways.⁶⁵

In the past 10 years, investigators have examined the role of apoptosis in varicose vein formation. In an earlier report, the apoptotic index was 48% in control veins and only 15% in varicose veins. Apoptosis was only observed in the adventitia, and immunoreactivity was similar for bcl-2 protein but cyclin D1 was significantly increased in varicose veins, indicating inhibition of apoptosis in varicose veins may be related to changes in the expression of cell cycle events.⁶⁶ To further explore the reduced apoptosis in varicose veins, the same authors examined the expression of bax protein and of poly ADP-ribose polymerase (PARP, involved in repair of DNA damage), which is inhibited by caspases 3 and 6 activation. In 20 patients with varicose

veins, the immunoreactivity expression of bax and PARP was decreased in the distal portion of the varicose veins compared with distal control vein specimens. In normal veins there was significantly higher immunoreactivity for bax. In addition, neither bax nor PARP were present in the adventitia of varicose veins, but was significantly expressed in control veins. These studies suggest that abnormal apoptosis may cause venous wall changes and dilation in varicose vein pathogenesis. Other studies support the role of changes in apoptosis regulatory proteins in varicose veins pathophysiology. A recent study evaluating the distal segment of varicose veins and controls, demonstrated disorganized architecture with increased collagen fibres and a decrease in the density and size of elastic fibres. In addition, varicose veins exhibited fewer immunoreactive cells for bax and caspase 9 in the media, suggesting that the dysregulation of the intrinsic pathway of apoptosis disrupts normal tissue integrity leading to varicose vein formation.⁶⁷

Smooth muscle cell dysfunction

Several studies have investigated cultured smooth muscle cells derived from varicose veins to determine if the ECM modifications seen in varicose vein tissue are related to smooth muscle cells. Smooth muscle cells cultured from varicose veins were found to have decreased number of cells staining for collagen type III and fibronectin compared with control veins, although the transcriptional products of these two proteins were not dissimilar in varicose veins vs. control vein. The synthesis and deposition of collagen type III but not type I was significantly lower in varicose veins. When MMPs (-1, -2, and -9) and TIMPs (-1 and -2) were analysed from the supernatant of confluent cells, no differences were observed. These data suggested that the regulation for both collagen type III and fibronectin in smooth muscle cells were altered during post-transcriptional events.⁶⁸ Although there were no differences in MMP and TIMP in the supernatant tested, this does not exclude the possibility that altered expression and activity of MMPs and TIMPs exist in whole tissues. Further work in this area demonstrated that varicose greater saphenous vein has a smaller spiralled collagen distribution specifically in the intima and media. To investigate this latter finding, the same investigators demonstrated that inhibition of MMP with marimastat (BB-2516, non-selective MMP inhibitor) resulted in partial restoration in the production of collagen type III in smooth muscle cells from varicose

veins. In addition, MMP-3, which degrades fibronectin, was elevated in both transcription product and protein expression. It was concluded that the mechanism involved in collagen type III and fibronectin degradation in the smooth muscle cells cultured from varicose veins is likely linked to the expression of MMP-3.⁶⁹ Taken together, these findings suggest that at least in cultured smooth muscle cells from varicose vein, there is an imbalance of collagen production with dysregulation and increased type I collagen, but suppressed type III collagen production. Because of normal expression of mRNA for type III collagen, the reduction in production is related to post-transcriptional events. The inhibition of type III collagen synthesis could be a result of degradation/inhibition by MMP-3 and may explain changes in mechanical properties (elasticity and distensibility) of the vein wall leading to varicose vein formation.

In further defining the morphological ECM components and the role of a systemic effect of varicose veins in patients with CVD, the expression of matrix proteins collagen type I, fibrillin-1 and laminin, as well as MMPs and TIMPs were examined. The control group was dermal biopsies and saphenous vein specimens from patients undergoing coronary revascularization. From this study, both dermal biopsies and varicose vein specimens had elevated matrix proteins and MMP-1, -2, and -3, but neither MMP-7 or -9 nor TIMPs (-1, -2 and -3). This study reinforced the notion of an imbalance in matrix production and degradation, and the systemic effect in different tissues of patients with varicose veins.⁷⁰ These studies raise the possibility that a skin biopsy may be useful to identify patients at risk for the development of CVD before clinical manifestations are even present.

Endothelial cell dysfunction

An increase in MMP immunoreactivity has been observed in the adventitia, endothelium and smooth muscles of the varicose vein wall.⁶⁰ The role of MMPs in varicose vein has largely been attributed to their proteolytic effects on the ECM, degradation of the valve leaflets and weakening of vein wall structure.^{71,72} The localization of MMPs in the varicose vein wall adventitia and fibroblast is consistent with a role in ECM degradation. On the other hand, the localization of MMPs in the vicinity of the venous endothelium and smooth muscle raises the possibility of an additional effect of MMPs on these cell types.^{60,73}

We have recently examined the acute effects of MMPs in the contractile function of the rat inferior vena cava and the role of the endothelium and smooth muscle during contraction and relaxation. We found that MMP-2 caused relaxation of phenylephrine contraction in the inferior vena cava.⁷⁴ The endothelium controls vascular tone through nitric oxide (NO) and prostacyclin (PGI₂), but also through hyperpolarization of the underlying smooth muscle cell by endothelial-derived hyperpolarizing factor (EDHF).⁷⁵ EDHF-mediated responses involve an increase in the intracellular calcium concentration, the opening of calcium-activated potassium channels of small and intermediate conductance and the hyperpolarization of the endothelial cells. The resulting endothelial hyperpolarization spreads via myoendothelial gap junctions to result in the EDHF-mediated hyperpolarization and relaxation of the smooth muscle.^{76–78} MMPs could increase PGI₂ synthesis and activate PGI₂-cAMP pathway, or increase EDHF release and enhance K⁺ efflux (K⁺ is extruded from the cell via K-channels) leading to venous tissue hyperpolarization and relaxation.⁷⁹ We have found that MMP-2-induced venous relaxation was essentially abolished in 96 mmol/L KCl depolarizing solution, which prevents outward movement of K⁺ from the cell through K⁺ channels. In order to define which K⁺ channels were involved, we tested the effects of K⁺ channel agonists and antagonists on MMP-2-induced venous relaxation. MMP-2 caused further relaxation of vein segments in the presence of activators of ATP-sensitive potassium (K_{ATP}) channel, indicating that MMP-2 is not working through the K_{ATP} channel during cell hyperpolarization. In contrast, blockade of the large conductance Ca²⁺-dependent K⁺ channels (BK_{Ca}) significantly inhibited the MMP-2 effect on venous relaxation, suggesting that MMP-2 actions, in part, involve hyperpolarization and activation of large conductance BK_{Ca}. MMP-2-induced activation of K⁺ channels likely causes smooth muscle hyperpolarization, and leads to decreased Ca²⁺ influx through voltage-gated channels. This is supported by a previous report which demonstrated that MMP-2 and MMP-9 cause aortic dilatation by inhibiting Ca²⁺ entry into aortic smooth muscle.⁸⁰ Taken together, these data demonstrate novel effects of MMPs on venous tissue function and suggest that protracted MMP-2-induced venous relaxation could lead to progressive venous dilatation, possibly influencing the venous wall before

changes in the valve occur, leading to varicose vein formation and CVD.⁷⁴

Conclusions

The pathogenesis of varicose vein formation is a complex process and likely multifactorial. Although the common clinical findings of CVD are both clinical manifestations and laboratory evidence of valvular insufficiency, it appears that the changes associated with incompetent valves are secondary to alterations in the vein wall. From the evidence presented, clinical studies have demonstrated that varicose veins can form in any segment of the limb, and tributaries that connect to axial veins can have varicosities without any reflux in the communicating vein. These findings are supported by basic scientific studies that have demonstrated alterations in vascular wall collagen: elastin ratios, in the absence of significant activity of proteinase and matrix degradation. Importantly, venous segments that are normal but in continuity to varicose veins have the same biochemical properties of the vein wall as varicose veins, suggesting that vein wall changes precede valvular changes. Although a genetic basis for varicose vein is unclear, certain gene mutations and variants have an important role in determining risk for advanced CVD. Furthermore, varicose vein pathology may have more than just a local affect on the veins of the extremity, but penetrate to other tissue in the body indicating that varicose vein formation may be a systemic disease and supporting a genetic basis.

Venous tissue homeostasis and turnover is a complex process and requires a balance between cell renewal, matrix deposition, remodelling and stability. Abnormal apoptosis in venous disease disrupts this balance, and favours accumulation of cellular elements and matrix in the wall structure of varicose veins. MMPs and their naturally occurring TIMPs have been implicated in numerous human diseases including varicose veins. The abundance of data demonstrating MMPs in venous tissue raises the possibility for a role in varicose vein formation. MMPs may have multiple roles that are temporally dependent on the stage of varicose vein development. In the early stages, MMPs may cause venous dilation by inducing hyperpolarization of the vein wall, and inhibiting proper and balanced production of collagen subtypes. In later stages of CVD, MMPs may alter the vein wall matrix composition to such an extent where dilation and tortuosity becomes

the prevailing morphological feature that is observed clinically in CVD.

Perspective

The elusive nature of varicose vein formation and its wide prevalence among individuals throughout the world make it necessary to understand the mechanisms involved in the pathogenesis of the disease. Little is known regarding the initiating events and progress of the disease, and most studies are cross-sectional evaluating disease at a given time in point. One area of focus could be a longitudinal epidemiological study, similar to the Framingham Heart Study.⁸¹ A longitudinal epidemiological venous study would aim at defining the natural determinants of varicose veins with respect to genetic predisposition, risk factors and environmental influences. Subjects from the general population with no evidence of venous disease would enrol at a young adulthood age, and be followed to the geriatric age. At specific yearly intervals, both genotyping and phenotypic characteristics including inflammatory markers of cardiovascular disease, hypercoagulation disorders would be determined. Parallel venous anatomical, morphological, and physiological studies with Duplex ultrasound and air plethysmography would be used to diagnose the anatomical regions as well as the severity of the CVD for possible correlation with predisposing genetic, environmental and other risk factors.

Genetic abnormalities for more severe forms of CVD have been described. Identifying a genetic basis for varicose vein will not only help elucidate the molecular abnormalities involved with that gene and its function, but also provide information on individuals at risk and guide in therapeutic decisions during treatment. An understanding of the molecular basis of varicose veins formation with respect to changes in endothelial cell and smooth muscle function, as well as the influence of abnormal apoptotic function and MMP involvement, will provide valuable information on the mechanisms involved in the disease development and progression, and highlight possible targets for pharmacological intervention or genetic manipulation of the disease.

Acknowledgements

This work was supported in part by grants from the National Heart, Lung, and Blood Institute (HL-65998 and HL-70659).

References

- 1 Eklof B, Rutherford RB, Bergan JJ, *et al.* Revision of the CEAP classification for chronic venous disorders: consensus statement. *J Vasc Surg* 2004;**40**:1248–52
- 2 Bergan JJ, Schmid-Schonbein GW, Coleridge-Smith PD, Nicolaides AN, Boisseau MR, Eklof B. Chronic venous disease. *N Engl J Med* 2006;**355**:488–98
- 3 Pollack AA, Wood EH. Venous pressure in the saphenous vein at the ankle in man during exercise and changes in posture. *J Appl Physiol* 1949;**1**:649–62
- 4 Recek C. Conception of the venous hemodynamics in the lower extremity. *Angiology* 2006;**57**:556–63
- 5 Zhou D, Lee HS, Villarreal F, *et al.* Differential MMP-2 activity of ligament cells under mechanical stretch injury: an in vitro study on human ACL and MCL fibroblasts. *J Orthop Res* 2005;**23**:949–57
- 6 Asanuma K, Magid R, Johnson C, Nerem RM, Gslis ZS. Uniaxial strain upregulates matrix-degrading enzymes produced by human vascular smooth muscle cells. *Am J Physiol Heart Circ Physiol* 2003;**284**:H1778–84
- 7 Milkiewicz M, Haas TL. Effect of mechanical stretch on HIF-1[alpha] and MMP-2 expression in capillaries isolated from overloaded skeletal muscles: laser capture microdissection study. *Am J Physiol Heart Circ Physiol* 2005;**289**:H1315–20
- 8 Schmid-Shonbein GW, Takase S, Bergan JJ. New advances in the understanding of the pathophysiology of chronic venous insufficiency. *Angiology* 2001;**52** (suppl. 1):S27–34
- 9 Visse R, Nagase H. Matrix metalloproteinases and tissue inhibitors of metalloproteinases: structure, function, and biochemistry. *Circ Res* 2003;**92**:827–39
- 10 Galis ZS, Khatir JJ. Matrix metalloproteinases in vascular remodeling and atherogenesis: the good, the bad, and the ugly. *Circ Res* 2002;**90**:251–62
- 11 Raffetto JD, Khalil RA. Matrix metalloproteinases and their inhibitors in vascular remodeling and vascular disease. *Biochem Pharmacol* 2008;**75**:346–59
- 12 Bergan JJ, Schmid-Shonbein GW, Coleridge-Smith PD, Nicolaides AN, Boisseau MR, Eklof B. Chronic venous disease. *N Engl J Med* 2006;**355**:488–98
- 13 Brand FN, Dannenberg AL, Abbott RD, Kannel WB. The epidemiology of varicose veins: the Framingham Study. *Am J Prev Med* 1988;**4**:96–101
- 14 Bradbury A, Evans C, Allan P, Lee A, Ruckley CV, Fowkes FG. What are the symptoms of varicose veins? Edinburgh vein study cross sectional population survey. *Br Med J* 1999;**318**:353–6
- 15 Evans CJ, Fowkes FG, Ruckley CV, Lee AJ. Prevalence of varicose veins and chronic venous insufficiency in men and women in the general population: Edinburgh Vein Study. *J Epidemiol Commun Health* 1999;**53**:149–53
- 16 Ruckley CV, Evans CJ, Allan PL, Lee AJ, Fowkes FG. Chronic venous insufficiency: clinical and duplex correlations. The Edinburgh Vein Study of venous disorders in the general population. *J Vasc Surg* 2002;**36**:520–5
- 17 Scott TE, LaMorte WW, Gorin DR, Menzoian JO. Risk factors for chronic venous insufficiency: a dual case-control study. *J Vasc Surg* 1995;**22**:622–8
- 18 Jawien A. The influence of environmental factors in chronic venous insufficiency. *Angiology* 2003;**54** (suppl. 1): S19–31
- 19 Lee AJ, Evans CJ, Allan PL, Ruckley CV, Fowkes FG. Lifestyle factors and the risk of varicose veins: Edinburgh Vein Study. *J Clin Epidemiol* 2003;**56**:171–9
- 20 Lacroix P, Aboyans V, Preux PM, Houles MB, Laskar M. Epidemiology of venous insufficiency in an occupational population. *Int Angiol* 2003;**27**:172–6
- 21 Christopoulos D, Nicolaides AN, Szendro G. Venous reflux: quantification and correlation with the clinical severity of chronic venous disease. *Br J Surg* 1988;**75**:352–6
- 22 Zamboni P, Scapoli GL, Lanzara V, *et al.* Serum iron and matrix metalloproteinase-9 in limbs affected by chronic venous disease and venous leg ulcers. *Dermatol Surg* 2005;**31**:644–9
- 23 Zamboni P, Izzo M, Tognazzo S, *et al.* The overlapping of local iron overload and HFE mutation in venous leg ulcer pathogenesis. *Free Radic Biol Med* 2006;**40**:1869–73
- 24 Zamboni P, De Mattei M, Ongaro A, *et al.* Factor XIII contrasts the effects of metalloproteinases in human dermal fibroblast cultured cells. *Vasc Endovasc Surg* 2004;**38**:431–8
- 25 Zamboni P, Tognazzo S, Izzo M, *et al.* Hemochromatosis C282Y gene mutation increases the risk of venous leg ulceration. *J Vasc Surg* 2005;**42**:309–14
- 26 Tognazzo S, Gemmati D, Pallazzo A, *et al.* Prognostic role of factor XIII gene variants in nonhealing venous leg ulcers. *J Vasc Surg* 2006;**44**:815–9
- 27 Gemmati D, Tognazzo S, Catozzi L, *et al.* Influence of gene polymorphisms in ulcer healing process after superficial venous surgery. *J Vasc Surg* 2006;**44**:554–62
- 28 Noel AA, Gloviczki P, Cherry KJ, Rooke TW, Stanson AW, Driscoll DJ. Surgical treatment of venous malformations in Klippel-Trenaunay syndrome. *J Vasc Surg* 2000;**32**:840–47
- 29 Delis KT, Gloviczki P, Wennberg PW, Rooke TW, Driscoll DJ. Hemodynamic impairment, venous segmental disease, and clinical severity scoring in limbs with Klippel-Trenaunay syndrome. *J Vasc Surg* 2007;**45**:561–7
- 30 Brice G, Mansour S, Bell R, *et al.* Analysis of the phenotypic abnormalities in lymphoedema-distichiasis syndrome in 74 patients with FOXC2 mutations or linkage to 16q24. *J Med Genet* 2002;**39**:478–83
- 31 Ng MY, Andrew T, Spector TD, Jeffery S. Lymphoedema Consortium. Linkage to the FOXC2 region of chromosome 16 for varicose veins in otherwise healthy, unselected sibling pairs. *J Med Genet* 2005;**42**:235–9
- 32 Saiki S, Sakai K, Saiki M, *et al.* Varicose veins associated with CADASIL result from a novel mutation in the Notch3 gene. *Neurology* 2006;**67**:337–9
- 33 Lee S, Lee W, Choe Y, *et al.* Gene expression profiles in varicose veins using complementary DNA microarray. *Dermatol Surg* 2005;**31**:391–5
- 34 Dalal A, Phadke SR. Hemihyperplasia with Ehlers-Danlos syndrome like skin changes. *Clin Dysmorphol* 2005;**14**:207–8
- 35 Badauy CM, Gomes SS, Sant'ana Filho M, Chies JA. Ehlers-Danlos Syndrome (EDS) type IV. Review of the literature. *Clin Oral Invest* 2007;**11**:183–7
- 36 McKusick VA. The defect in Marfan syndrome. *Nature* 1991;**352**:279–81
- 37 Sansilvestri-Morel P, Rupin A, Jaisson S, Fabiani JN, Verbeuren TJ, Vanhoutte PM. Synthesis of collagen is dysregulated in cultured fibroblasts derived from skin of subjects with varicose veins as it is in venous smooth muscle cells. *Circulation* 2002;**106**:479–83
- 38 Sansilvestri-Morel P, Rupin A, Badier-Commander C, Fabiani JN, Verbeuren TJ. Chronic venous insufficiency:

- dysregulation of collagen synthesis. *Angiology* 2003;**54** (suppl. 1):S3–8
- 39 Labropoulos N, Tiongson J, Pryor L, *et al.* Definition of venous reflux in lower extremity veins. *J Vasc Surg* 2003;**38**:793–8
- 40 Labropoulos N, Giannoukas AD, Delis K, *et al.* Where does venous reflux start? *J Vasc Surg* 1997;**26**:736–42
- 41 Labropoulos N, Kang SS, Mansour MA, Giannoukas AD, Buckman J, Baker WH. Primary superficial vein reflux with competent saphenous trunk. *Eur J Vasc Endovasc Surg* 1999;**18**:201–6
- 42 Labropoulos N, Leon L, Kwon S, *et al.* Study of venous reflux progression. *J Vasc Surg* 2005;**41**:291–5
- 43 Caggiati A, Rosi C, Heyen R, Franceschini M, Acconcia MC. Age-related variations of varicose veins anatomy. *J Vasc Surg* 2006;**44**:1291–5
- 44 Gandhi RH, Irizarry E, Neckman GB, Halpern VJ, Mulcare RJ, Tilson MD. Analysis of the connective tissue matrix and proteolytic activity of primary varicose veins. *J Vasc Surg* 1993;**20**:814–20
- 45 Parra JR, Cambria RA, Hower CD, *et al.* Tissue inhibitor of metalloproteinase-1 is increased in the saphenofemoral junction of patients with varices in the leg. *J Vasc Surg* 1998;**28**:669–75
- 46 Badier-Commander C, Verbeuren T, Lebard C, Michel JB, Jacob MP. Increased TIMP/MMP ratio in varicose veins: a possible explanation for extracellular matrix accumulation. *J Pathol* 2000;**192**:105–12
- 47 Kirsch D, Wahl W, Bottger T, Junginger T. Primary varicose veins – changes in the venous wall and elastic behavior. *Chirurg* 2000;**71**:300–5
- 48 Kirsch D, Dienes HP, Kuchle R, *et al.* Changes in the extracellular matrix of the vein wall – the cause of primary varicosis? *Vasa* 2000;**29**:173–7
- 49 Thomas PR, Nash GB, Dormandy JA. White cell accumulation in dependent legs of patients with venous hypertension: a possible mechanism for trophic changes in the skin. *Br Med J* 1988;**296**:1693–5
- 50 Saharay M, Shields DA, Porter JB, Scurr JH, Coleridge-Smith PD. Leukocyte activity in the microcirculation of the leg in patients with chronic venous disease. *J Vasc Surg* 1997;**26**:265–73
- 51 Takase S, Schmid-Shonbein GW, Bergan JJ. Leukocyte activation in patients with venous insufficiency. *J Vasc Surg* 1999;**30**:148–56
- 52 Powell CC, Rohrer MJ, Barnard MR, Peyton BD, Furman MI, Michelson AD. Chronic venous insufficiency is associated with increased platelet and monocyte activation and aggregation. *J Vasc Surg* 1999;**30**:844–51
- 53 Takase S, Bergan JJ, Schmid-Shonbein G. Expression of adhesion molecules and cytokines on saphenous veins in chronic venous insufficiency. *Ann Vasc Surg* 2000;**14**:427–35
- 54 Delis KT, Husmann M, Kalodiki E, Wolfe JH, Nicolaidis AN. In situ hemodynamics of perforating veins in chronic venous insufficiency. *J Vasc Surg* 2001;**33**:773–82
- 55 Vanscheidt W, Rabe E, Naser-Hijazi B, *et al.* The efficacy and safety of coumarin-troloxerutin-combination (SB-LOT) in patients with chronic venous insufficiency: a double blind placebo-controlled randomized study. *Vasa* 2002;**31**:185–90
- 56 Siebert U, Brach M, Sroczynski G, Berla K. Efficacy, routine effectiveness, and safety of horse chestnut seed extract in the treatment of chronic venous insufficiency. A meta-analysis of randomized controlled trials and large observational studies. *Int Angiol* 2002;**21**:305–15
- 57 Takase S, Pascarella L, Lerond L, Bergan JJ, Schmid-Shonbein GW. Venous hypertension, inflammation and valve remodeling. *Eur J Vasc Endovasc Surg* 2004;**28**:484–93
- 58 Jacob MP, Cazaubon M, Scemama A, *et al.* Plasma matrix metalloproteinase-9 as a marker of blood stasis in varicose veins. *Circulation* 2002;**106**:535–8
- 59 Gillespie DL, Patel A, Fileta B, *et al.* Varicose veins possess greater quantities of MMP-1 than normal veins and demonstrate regional variation in MMP-1 and MMP-13. *J Surg Res* 2002;**106**:233–8
- 60 Woodside KJ, Hu M, Burke A, *et al.* Morphologic characteristics of varicose veins: possible role of metalloproteinases. *J Vasc Surg* 2003;**38**:162–9
- 61 Kosugi I, Urayama H, Kasashima F, Ohtake H, Watanabe Y. Matrix metalloproteinase-9 and urokinase-type plasminogen activator in varicose veins. *Ann Vasc Surg* 2003;**17**:234–8
- 62 Kowalewski R, Sobolewski K, Wolanska M, Gacko M. Matrix metalloproteinases in the vein wall. *Int Angiol* 2004;**23**:164–9
- 63 Takase S, Pascarella L, Bergan JJ, Schmid-Schonbein GW. Hypertension-induced venous valve remodeling. *J Vasc Surg* 2004;**39**:1329–34
- 64 Pascarella L, Schmid-Schonbein GW, Bergan JJ. An animal model of venous hypertension: the role of inflammation in venous valve failure. *J Vasc Surg* 2005;**41**:303–11
- 65 Green DR, Reed JC. Mitochondria and apoptosis. *Science* 1998;**281**:1309–12
- 66 Ascher E, Jacob T, Hingorani A, Gunduz Y, Mazzariol F, Kallakuri S. Programmed cell death (apoptosis) and its role in the pathogenesis of lower extremity varicose veins. *Ann Vasc Surg* 2000;**14**:24–30
- 67 Ducasse E, Giannakakis K, Chevalier J, *et al.* Dysregulated apoptosis in primary varicose veins. *Eur J Vasc Endovasc Surg* 2005;**29**:316–23
- 68 Sansilvestri-Morel P, Nonotte I, Fournet-Bourguignon MP, *et al.* Abnormal deposition of extracellular matrix proteins by cultured smooth muscle cells from human varicose veins. *J Vasc Res* 1998;**35**:115–23
- 69 Sansilvestri-Morel, Rupin A, Jullien ND, *et al.* Decreased production of collagen type III in cultured smooth muscle cells from varicose vein patients is due to a degradation by MMPs: possible implication of MMP-3. *J Vasc Res* 2005;**42**:388–98
- 70 Sansilvestri-Morel, Fioretti F, Rupin A, *et al.* Comparison of extracellular matrix in skin and saphenous veins from patients with varicose veins: does the skin reflect venous matrix changes? *Clin Sci (Lond)* 2007;**112**:229–39
- 71 Pascarella L, Penn A, Schmid-Schonbein GW. Venous hypertension and the inflammatory cascade: major manifestations and trigger mechanisms. *Angiology* 2005;**56** (suppl. 1):S3–10
- 72 Herouy Y, Nockowski P, Schopf E, Norgauer J. Lipodermatosclerosis and the significance of proteolytic remodeling in the pathogenesis of venous ulceration. *Int J Mol Med* 1999;**3**:511–5
- 73 Thulesius O. The venous wall and valvular function in chronic venous insufficiency. *Int Angiol* 1996;**15**:114–8
- 74 Raffetto JD, Ross RL, Khalil RA. Matrix metalloproteinase-2 induced venous dilation via hyperpolarization

- and activation of K⁺ channels. Relevance to varicose vein formation. *J Vasc Surg* 2007;**45**:373–80
- 75 Feletou M, Vanhoutte PM. Endothelium-derived hyperpolarizing factor: where are we now? *Arterioscler Thromb Vasc Biol* 2006;**26**:1215–25
- 76 Cai WJ, Kocsis E, Luo X, Schaper W, Schaper J. Expression of endothelial nitric oxide synthase in the vascular wall during arteriogenesis. *Mol Cell Biochem* 2004;**264**:193–200
- 77 Coleman HA, Tare M, Parkington HC. Endothelial potassium channels, endothelium-dependent hyperpolarization and the regulation of vascular tone in health and disease. *Clin Exp Pharmacol Physiol* 2004;**31**:641–9
- 78 Coleman HA, Tare M, Parkington HC. K⁺ currents underlying the action of endothelium-derived hyperpolarizing factor in guinea pig, rat and human blood vessels. *J Physiol* 2001;**531**:359–73
- 79 Cohen RA. The endothelium-derived hyperpolarizing factor puzzle. A mechanism without a mediator? *Circulation* 2005;**111**:724–7
- 80 Chew DKW, Conte MS, Khalil RA. Matrix metalloproteinase-specific inhibition of Ca²⁺ entry mechanisms of vascular contraction. *J Vasc Surg* 2004;**40**:1001–10
- 81 Dawber TR, Kannel WB. The Framingham study. An epidemiological approach to coronary heart disease. *Circulation* 1966;**34**:553–5